



American Journal of Anesthesia & Clinical Research

Mini Review

Pain Management in Multiple Fractured Ribs; Role of Regional Analgesia - ①

Ashok Jadon*

Department of Anaesthesia & Pain Relief Service, Chief Consultant & Head Of Department, Tata Motors Hospital, Jamshedpur-831004

***Address for Correspondence:** Ashok Jadon, Department of Anaesthesia & Pain Relief Service, Chief Consultant & Head of Department, Tata Motors Hospital, Jamshedpur-831004, India, Tel: +91-9234554341; E-mail: jadona@rediffmail. com

Submitted: 03 March 2017; **Approved:** 21 March 2017; **Published:** 23 March 2017

Citation this article: Jadon A. Pain Management in Multiple Fractured Ribs; Role of Regional Analgesia. American J Anesth Clin Res. 2017;3(1): 020-026.

Copyright: © 2017 Jadon A. This is an open access article distributed under the Creative Commons Attribution License, which permits unrestricted use, distribution, and reproduction in any medium, provided the original work is properly cited.

ABSTRACT

Blunt trauma of chest wall is the commonest cause of rib fracture. Patients with fracture of one or two ribs have low incidences of complications however; fractures of three or more ribs (Multiple Fractured Ribs, MFRs) have increased risk of morbidity and mortality. When multiple ribs are fractured pain relief with systemic opioids can result in over-sedation, inability for expectoration and worsening of pulmonary condition. In MFRs regional mode of analgesia is a preferred choice in the pain management. There are several regional analgesia techniques which can be used however; each technique has advantages and limitation for its usage. In current practice ultrasound guided interfascial plane blocks like serratus anterior plane block, rhomboid intercostal plane block and erector spinae plane block may provide effective pain relief without posing serious risk of procedure itself. This brief review has discussed various regional technique of pain relief in MFRs.

Keywords: Intercostal block; Interfacial plane block; Multiple fractured ribs; Pain management; Regional analgesia; Thoracic epidural; Ultrasound guided block

INTRODUCTION

Blunt trauma of chest wall is the commonest cause of rib fracture [1,2]. Patients with fracture of one or two ribs have low incidences of complications [1,3] and can easily be managed with oral analgesic drugs (NSAIDs, acetaminophen) [4]. However, patient with fractures of three or more ribs (Multiple Fractured Ribs, MFRs) have increased risk of morbidity and mortality [1]. The risk of mortality is influenced by the amount of pain a patient experience. In cases of multiple rib fractures pain is usually more severe and frequently alters pulmonary mechanics. Increased pain during breathing causes shallow breath and ineffective coughing, which results in insufficient clearance of airway secretions and retention of sputum which often precipitates secondary complications [3,5,6]. Inadequate pain relief results in reduced lung compliance and ventilation-perfusion Mismatch. The combination of poor lung compliance and inadequate clearance of secretions leads to atelectasis, sepsis and pneumonia. Eventually intubation and ventilator support may be required for respiratory failure. These complications can be avoided with adequate pain relief [4,7].

Regional Techniques of Pain Relief

When multiple ribs are fractured pain relief with systemic narcotics can result in over-sedation, inability for expectoration and worsening of pulmonary condition. Therefore, when multiple ribs are fractured, regional mode of analgesia is a preferred choice in the pain management. There are several regional analgesia techniques which can be used however; each technique has advantages and limitation for its usage (Table 1). Regional techniques used to provide analgesia in multiple rib fracture are given below:

Intercostal Nerve Block (ICNB)

The intercostal nerve block is aimed at the ventral ramus of the sensory nerve that runs in the small neurovascular bundle at the inferior aspect of each rib (Figure 1). The Intercostal Nerve Block (ICNB) is an effective and simple method for pain relief however, it has many practical difficulties. First of all, many injections have to be given depending on the numbers of fracture ribs. The duration of relief is also a limitation. Studies have reported good relief up to 6-8 hrs. Only and, repeated injections become less effective [8]. Injury to the neurovascular bundle and pneumothoraces are other possible complications. Due to high absorption of local anaesthetic drugs by intercostal muscles adrenaline should be used which helps to reduce systemic absorption of local anesthetic by vasoconstriction of local vasculature. To avoid toxicity of local anaesthetic dosages also should to be kept in safe limits.

The landmark-based approach is performed at the posterior axillary line where the ribs can be easily palpated. This is often lateral to the division of the intercostal nerve into deep and lateral cutaneous branches and may therefore result in good anesthesia of the rib but poor anesthesia of pleura. Ultrasound guided intercostal block enables visualization of local anesthetic injection into the intercostal space, allowing the provider to adjust the needle trajectory and depth as needed to ensure adequate anesthetic spread [9]. In 1988, Vaghadia and Jenkins, et al. [10] described the use of Doppler ultrasound in three patients for Intercostal Nerve Block. The authors felt that the advantage was location of the ribs by a less painful and a more accurate method (in obese patients) than palpation. Further studies are needed to investigate the effect of intercostal nerve blockade on pain reduction and patient satisfaction and to compare intercostal nerve blockade to other analgesic strategies.

Continuous Intercostal Nerve Block

In patients with contraindications to epidural placement this technique could be a therapeutic alternative [11,12]. This technique can also be used safely in a patient who may be coagulopathic. These catheters are inserted lateral to the paraspinous muscles and tunneled perpendicular and superficial to the affected ribs in an extra thoracic location where the incidence of morbidity from a hematoma is low. In a patient taking clopidogrel as part of a regimen to treat coronary artery disease after stent placement, this technique would have allowed continuation of their antiplatelet therapy as well as alleviating the concern for neuraxial hematoma. In addition, with proper attention to issues of consent, this modality can be used in the

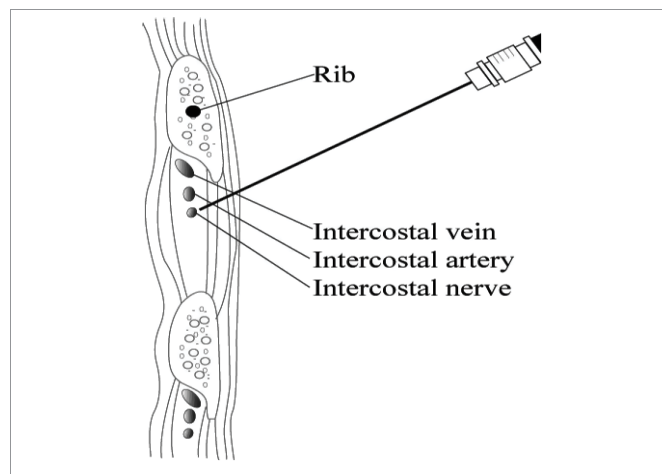


Figure 1: Intercostal Nerve Block.

patient who has already been intubated, where sedation and lack of patient cooperation make the risks associated with a thoracic epidural placement unacceptable.

Thoracic Para-Vertebral Block (TPB)

Injection of local anaesthetic in to thoracic paravertebral space (Figure 2) is very effective for pain relief in cases with rib fractures [13]. For multiple rib fractures, catheter technique is preferred which can provide continuous pain relief. Single injection technique requires multiple and multi-level injections which has inherent risk of complications and also inconvenient to patients. TBP has been found to be as good analgesic technique as Thoracic Epidural Analgesia [5] and is also technically less complex, with minimal hemodynamic disturbance and no concern of urinary retention or pruitis [14]. One distinct advantage to PVB catheters over TEA is the ability to provide long-duration analgesia (60 hrs to 18 days) in the ambulatory setting which facilitate early ambulation and discharge from hospital [15,16]. However, there is a small risk for pneumothorax [17], vascular puncture, pleural puncture and a possibility of toxicity due to the rapid absorption of Local Anaesthetic [4]. TBP can be given by using surface landmarks, nerve stimulator guidance or Ultrasound Guidance (USG). A review suggested that USG blocks are more successful and safe then other techniques [18].

Intrapleural analgesia

For an intrapleural block, LA is deposited between the visceral and parietal layers of the pleura (Figure 3). This is usually done by inserting a catheter (A simple 18G epidural catheter can be inserted in mid axillary or posterior axillary line using Tuohy needle) and injecting local anaesthetic through that catheter either bolus or as continuous infusion. This is not a popular technique at present due to variable efficacy and side effects. Study by Bachman-Mennenga, et al. [19], and colleagues found that 70% of patients receiving the intrapleural anaesthetic needed supplemental opioids to manage pain. Other issue is the presence of a chest drain, which can cause loss of Local Anaesthetic [20]. Sometime the Local Anaesthetic can result in paralysis of the phrenic nerve and/or aggravate Bronchospasm [21]. There is also a risk for symptomatic pneumothorax [22]. If blood is present in the pleural space, the local anaesthetic will be diluted, resulting in a poor block. The rate of absorption may be rapid leading to a high plasma concentration and thus a potential risk for anaesthetic toxicity [2].

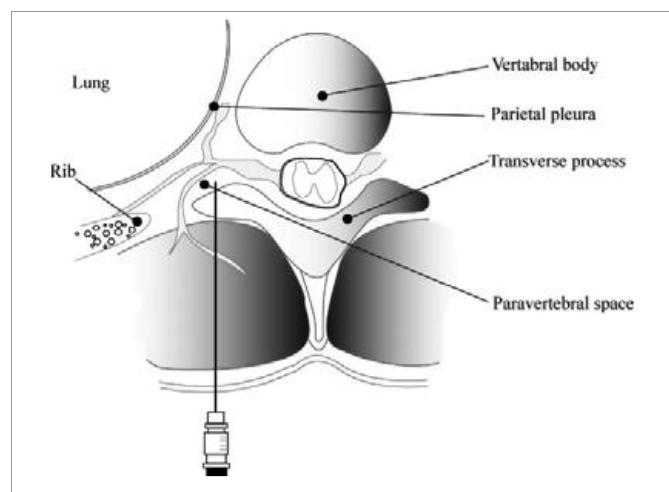


Figure 2: Thoracic Paravertebral Block.

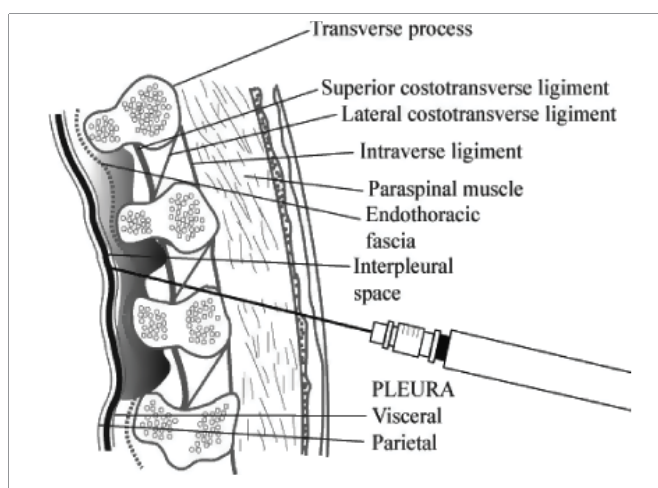


Figure 3: Intrapleural Nerve Block.

Epidural Analgesia (EA)

Epidural analgesia is a gold standard for pain relief in Multiple Fractured Ribs (MFRs) [23,24]. Lumbar as well as thoracic epidural analgesia with local anesthetic or with opioids combination has been successfully used to manage pain in patients with MFRs [24]. Epidural analgesia produces superior pain relief than other technique of pain relief and also modifies the immune response in patients with chest trauma, as evidenced by a [26,27] reduction in the plasma levels of interleukin (IL)-8 [25]. Use of EA reduces the respiratory complications and length of hospital stay. However, EA is technically demanding, especially in patients distressed with pain. In patients with multiple injuries, it may cause hypotension, can result in cardiovascular collapse and cardiac arrest in the inadequately resuscitated patient. Rarely may it cause other serious complications like infection & respiratory depression. Other undesirable side effects are nausea, vomiting, urinary retention, and pruritus. Moreover, one must also consider the possibility of inadvertent dural puncture, epidural hematoma and, very rarely, spinal cord trauma after EA.

Intrathecal opioids

Intrathecal morphine via the lumbar route has been used for analgesia in MFRs [28,29]. The efficacy to control pain is variable and a study has suggested that epidural bupivacaine is superior in analgesia [29].

Epidural steroids

Rauchwerger, et al. [30] reported that pain could be controlled by injecting anaesthetics or steroids into the thoracic epidural space; it was reported to be effective for bilateral rib fractures. Injection of 80 mg depot Methylprednisolone or Triamcinolone with 0.125 % bupivacaine (3-6 ml) in cases of multiple rib fractures can be used as a sole therapy or as an adjuvant to other analgesics.

NEW REGIONAL ANALGESIA TECHNIQUE

Serratus Anterior Plane Block (SAPB), Serratus-Intercostal Plane Block (SIFB), and Pecto-Intercostal Fascial Plane Block (PIFB)

Ultrasound-guided serratus anterior Plane block has recently been described to treat patients MFRs as a regional anesthetic technique to provide analgesia (Figure 4) [31,32]. SAP block provides analgesia to a hemithorax by blocking the lateral branches of the

Intercostal Nerves [33]. SAP block has also been reported to provide analgesia and to facilitate weaning from mechanical ventilation in critical care patients with MFR [35]. In this study Lopez-Matamala, et al. [34] used the similar targets (Lateral cutaneous branches) but used different nomenclature (SIFB). In this case series an additional block (PIFB) was used to block anterior cutaneous branches of Intercostal Nerves [34]. However, the benefit of giving additional interfacial block (PIFB) in management of MFRs is yet to be proved. Serratus plane block appear to be a safe, reliable means of improving pain relief following multiple rib fractures in trauma patients [35]. However, if ribs are fractured in posterior 1/3 part, the pain relief may not be adequate and may require thoracic epidural block [36].

Parasternal Block (PSB) and Transverse Thoracic Muscle Plane Block (TTP)

Fractures of ribs in anterior part including sternal fractures are painful condition which can result in pulmonary morbidity if not treated promptly. This area is supplied with anterior cutaneous branches of intercostal nerve (Figure 1). These nerves can be blocked by injection of local anesthetic in a plane between internal intercostal muscles and transverse thoracic muscle. Ueshima and Kitamura, et al. [37] described this block first time and named TTP. They used it for surgery of breast however, similar block given for sternal fracture at parasternal area was called PSB by Thomas, et al. [38] to give this block, at the lateral border of the sternum, and internal thoracic vessels lying anterior to transverse thoracic muscle are identified. The needle is inserted in-plane to follow its tip perfectly beyond the internal intercostal muscles, anterior to the transverse thoracic muscle to block the terminal anterior branch of the intercostal nerve and spread of local anaesthetic to the perivascular sympathetic plexus. To prevent pneumothorax or pericardium puncture these blocks are reserved for experienced people.

Rhomboid Intercostal Block (RICPB)

Recently an injection of local anaesthetic below the rhomboid

muscle (between rhomboid and Intercostal Muscle) was given in the area of Triangle of Auscultation (TOA) [39]. That provided the symptomatic relief in a case of fractured rib. The dermatomal coverage measured from T2-9 on the whole anterior hemithorax just medial from the midline, lateral from the axilla to T9, and on the posterior hemithorax T2-9 until immediately medial to the spinous processes. This result suggests Rhomboid Intercostal Block (RICPB) may be useful in providing analgesia for both the anterior and posterior hemithorax, but further comparisons with previously described blocks are required.

Erector Spinae Plane Block (ESPB)

The Sonoanatomy image to give ESPB is shown in (Figure 5A) and site of injection in (Figure 5B). RICPB and ESPB both work on the same target point i. e. , the dorsal and ventral ramus of thoracic spinal nerve through costotransverse foramen however; ESPB has wider coverage of dermatomes than RICPB [40,41]. These blocks provide more consistent and complete block of Intercostal nerve and their communicating branches [42] than Serratus Anterior Block [32,33]. Because the primary target in SAPB is lateral cutaneous branches [43].

Transcutaneous Electrical Nerve Stimulation (TENS)

This method of pain relief works through release of endorphins and studies have shown effective pain relief in MFRs [44,45]. However, one study have not mentioned the extent of fractured ribs [44] and other studies have used it in uncomplicated minor rib fracture [45] it is difficult to extrapolate the utility of TENS in various degree of MFRs.

Transdermal lidocaine patches

Transdermal Lidocaine Patches [46] placed over rib fracture sites have not been shown to significantly improve pain control in patients with traumatic rib fractures.

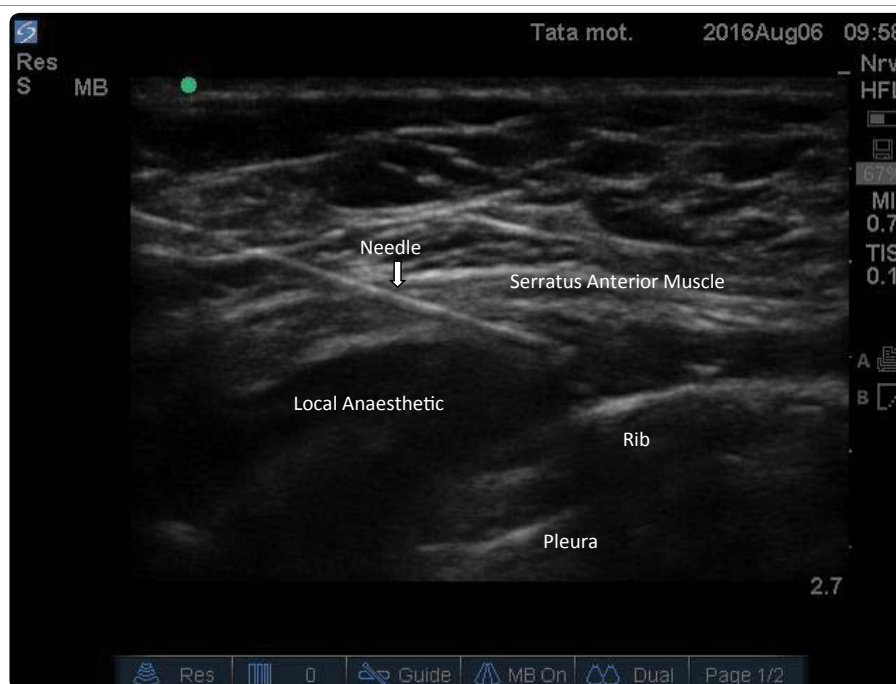


Figure 4: Serratus Anterior Plane Block, local Anaesthetic spread below the Serratus Anterior Muscle.

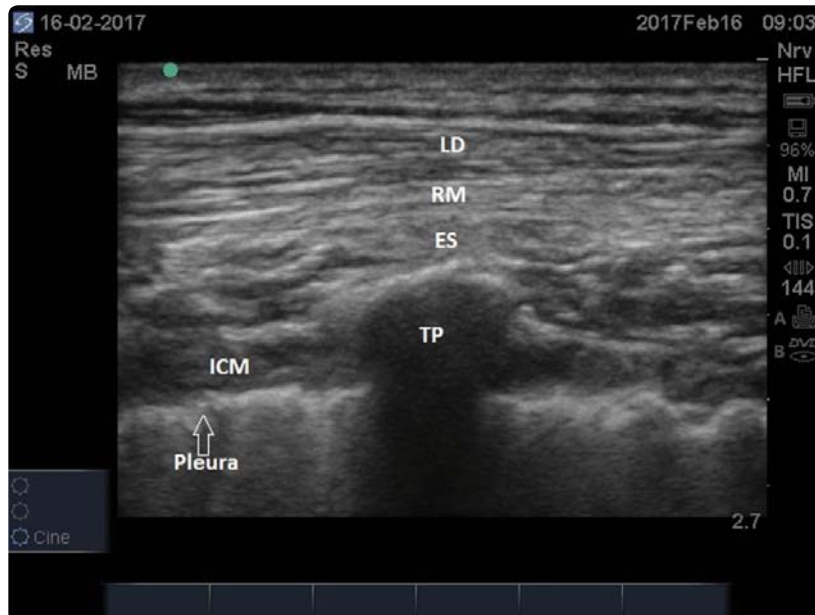


Figure 5a: Sonoanatomy of Erector Spinae Plane block, LD- Latissimus Dorsi, RM- Rhomboid Major, ES- Erector Spinae, TP- Transverse Process, ICM- Intercostal Muscles.

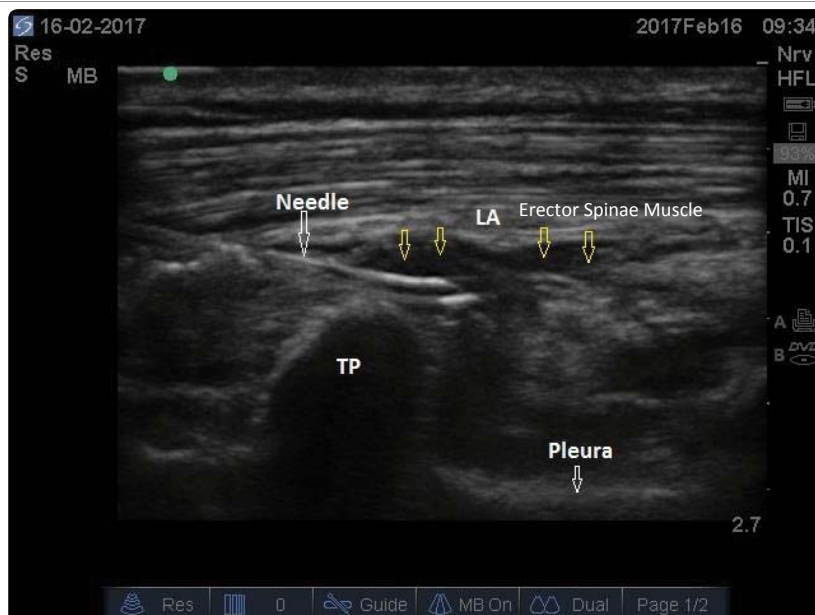


Figure 5b: Erector Spinae Plane Block, Block needle is touching the transverse process and colored arrows showing local anaesthetic spread below the erector spinae muscle.

Cervical epidural

Author has used this technique successfully to treat MFRs in two patients (Unpublished data). However, due to possibility of life-threatening complications and availability of relatively safe and effective alternatives its routine use is not suggested.

Chronic pain after MFRs

Prolonged chest wall pain is common after fractured ribs [47]. The prevalence is between 20-28 % however, no injury characteristics or therapy can predict chronic pain [48]. Various regional techniques

[39,40,49,50] have shown the reduction of chronic pain incidence after chest wall surgery. However, further investigation into more effective therapies that prevent prolonged pain and disability after rib fractures is needed [48].

CONCLUSION

Early and adequate management of pain due to fractured rib is essential. Inadequate pain management may lead to significant morbidity and may risk life threatening complications. Single rib fracture pain is easy to treat however pain due to fracture of multiple ribs require more intensive approach. Regional analgesic techniques



are very safe and effective technique either as a sole technique or as adjuvant. There are many techniques however, any particular method of analgesia for all patients could not be recommended. Individualized treatment technique has to be based on age, level of pain, and extent of the injury.

REFERENCES

- Lee RB, Bass SM, Morris JJ, Mackenzie EJ. Three or more rib fractures as an indicator for transfer to a level I trauma center: a population-based study. *J Trauma*. 1990; 30: 689-694. <https://goo.gl/MTv7ea>
- Ziegler DW, Agarwal NN. The morbidity and mortality of rib fractures. *J Trauma*. 1994; 37: 975-979. <https://goo.gl/AeNXBz>
- Flagel BT, Luchette FA, Reed RL, Esposito TJ, Davis KA, Santaniello JM, et al. Half-a-dozen ribs: the breakpoint for mortality. *Surgery*. 2005; 138: 717-723. <https://goo.gl/LtkB56>
- Ho AM, Karmakar MK, Critchley LA. Acute pain management of patients with multiple fractured ribs: a focus on regional techniques. *Curr Opin Crit Care*. 2011; 17: 323-327. <https://goo.gl/xe78xF>
- Mohta M, Verma P, Saxena AK, Sethi AK, Tyagi A, Girotra G. Prospective, Randomized Comparison of Continuous Thoracic Epidural and Thoracic Paravertebral Infusion in Patients With Unilateral Multiple Fractured Ribs--A Pilot Study. *J Trauma*. 2009; 66: 1096-1101. <https://goo.gl/vkxSG1>
- Karmakar MK, Ho AM. Acute pain management of patients with multiple fractured ribs. *J Trauma*. 2003; 54: 615-625. <https://goo.gl/l4KaRn>
- Doss NW, Veliyaniparambil I, Krishnan R, Gintautas J, Abadir AR. Continuous thoracic epidural ropivacaine drips for multiple rib fractures. *Proc West Pharmacol Soc*. 1999; 42: 99-100. <https://goo.gl/pBCMVo>
- Hwang EG, Lee Y. Effectiveness of intercostal nerve block for management of pain in rib fracture patients. *J Exerc Rehabil*. 2014; 10: 241-244. <https://goo.gl/uuA8d2>
- Stone MB, Carnell J, Fischer JW, Herring AA, Nagdev A. Ultrasound-guided intercostal nerve block for traumatic pneumothorax requiring tube thoracostomy. *Am J Emerg Med*. 2011; 29: 697. <https://goo.gl/wlYMnl>
- Vaghadia H, Jenkins LC. Use of a Doppler ultrasound stethoscope for intercostal nerve block. *Can J Anaesth*. 1988; 35: 86-89. <https://goo.gl/0OsuJ>
- Flores RA (Jr.), Ortiz J, Markan S. Multilevel Continuous Intercostal Nerve Block Catheter: A Viable Alternative to Thoracic Epidural for Multiple Rib Fractures?. *Anesthesiology*. 2013; 119: 987-996. <https://goo.gl/YfmX33>
- Truitt MS, Murry J, Amos J, Lorenzo M, Mangram A, Dunn E, et al. Continuous intercostal nerve blockade for rib fractures: Ready for primetime? *J Trauma*. 2011; 71: 1548-1552. <https://goo.gl/L0vMEY>
- Karmakar MK, Critchley LA, Ho AM, Gin T, Lee TW, Yim AP. Continuous thoracic paravertebral infusion of bupivacaine for pain management in patients with multiple fractured ribs. *Chest*. 2003; 123: 424-431. <https://goo.gl/hcOq3j>
- Karmakar M, Ho A. Thoracic and lumbar paravertebral block. In: *AdmirHadzic. ed. The New York School of Regional Anesthesia & Clinical Research textbook of regional anesthesia and acute pain management*. New York: McGraw-Hill; 2007: 583-597. <https://goo.gl/ERnpBV>
- Murata H, Salviz EA, Chen S, Vandepitte C, Hadzic A. Case report: ultrasound-guided continuous thoracic paravertebral block for outpatient acute pain management of multilevel unilateral rib fractures. *AnesthAnalg*. 2013; 116: 255-257. <https://goo.gl/tVD5Dq>
- Buckley M, Edwards H, Buckenmaier CC, 3rd, Plunkett AR. Continuous thoracic paravertebral nerve block in a working anesthesia resident-when opioids are not an option. *Mil Med*. 2011; 176: 578-580. <https://goo.gl/D3vLhh>
- Gann DS, Lilly MP. The neuroendocrine response to multiple trauma. *World J Surg*. 1983; 7: 101-118. <https://goo.gl/HxrnRv>
- Batra RK, Krishnan K, Agarwal A. Paravertebral Block. *J Anaesthesiol Clin Pharmacol*. 2011; 27: 5-11. <https://goo.gl/WzEFZI>
- Bachmann-Mennenga B, Biscopong J, Kuhn DF, Schürg R, Ryan B, Erkens U, et al. Intercostal nerve block, interpleural analgesia, thoracic epidural block or systemic opioid application for pain relief after thoracotomy? *Eur J Cardiothorac Surg*. 1993; 7: 12-18. <https://goo.gl/n04c26>
- Ferrante FM, Chan VW, Arthur GR, Rocco AG. Interpleural analgesia after thoracotomy. *AnesthAnalg*. 1991; 72: 105-109. <https://goo.gl/GbBLKQ>
- Lauder GR. Interpleural analgesia and phrenic nerve paralysis. *Anaesthesia*. 1993; 48: 315-316. <https://goo.gl/HlBH86>
- Murphy D. Intercostal nerve blockade for fractured ribs and postoperative analgesia: description of a new technique. *Reg Anesth*. 1983; 8: 151-153. <https://goo.gl/wlnxy4>
- Seltzer JL, Larijani GE, Goldberg ME, Marr AT. Intrapleural bupivacaine--a kinetic and dynamic evaluation. *Anesthesiology*. 1987; 67: 798-800. <https://goo.gl/meS8GW>
- Pierre E, Martin P, Frohock J, Varon A, Barquist E. Lumbar epidural morphine versus patient-controlled analgesia morphine in patients with multiple rib fractures. *Anesthesiology*. 2005; 103: A289. <https://goo.gl/nK4OUq>
- Moon MR, Luchette FA, Gibson SW, Crews J, Sudarshan G, Hurst JM, et al. Prospective, Randomized Comparison of Epidural Versus Parenteral Opioid Analgesia in Thoracic Trauma. *Ann Surg*. 1999; 229: 684-691. <https://goo.gl/pzRVzo>
- Waqar SH, Nasir K, Zahid MA. Thoracic epidural analgesia versus intravenous opioid analgesia for the treatment of rib fracture pain. *International Journal of Collaborative Research on Internal Medicine & Public Health*. 2013; 5: 112-119. <https://goo.gl/hC5QvS>
- Ullman DA, Wimpy RE, Fortune JB, Kennedy TM, Greenhouse BB. The treatment of patients with multiple rib fractures using continuous thoracic epidural narcotic infusion. *Reg Anesth*. 1989; 14: 43-47. <https://goo.gl/08Uur4>
- Kennedy BM. Intrathecal morphine and multiple fractured ribs. *Br J Anaesth*. 1985; 57: 1266-1267. <https://goo.gl/xEjlln>
- Dickson GR, Sutcliffe AJ. Intrathecal morphine and multiple fractured ribs. *Br J Anaesth*. 1986; 58: 1342-1343. <https://goo.gl/CCOqBR>
- Rauchwerger JJ, Candido KD, Deer TR, Frogel JK, Iadevaio R, Kirschen NB. Thoracic epidural steroid injection for rib fracture pain. *Pain Practice*. 2013; 13: 416-421. <https://goo.gl/Z5F2ia>
- Kunhabdulla NP, Agarwal A, Gaur A, Gautam SK, Gupta R, Agarwal A. Serratus anterior plane block for multiple rib fractures. *Pain Physician* 2014; 17: E651-E653. <https://goo.gl/liz1zzd>
- Jadon A, Jain P. Serratus Anterior Plane Block-An Analgesic Technique for Multiple Rib Fractures: A Case Series. *American J Anesth Clin Res*. 2017; 3: 001-004. <https://goo.gl/5A3oWh>
- Blanco R, Parras T, McDonnell JG, Prats-Galino A. Serratus plane block: a novel Ultrasound guided thoracic wall nerve block. *Anaesthesia*. 2013; 68: 1107-1113. <https://goo.gl/jRst67>
- Lopez-Matamala B, Fajardo M, Estebanez-Montiel B, Blancas R, Alfaro P, Chana M. A new thoracic interfascial plane block as anesthesia for difficult weaning due to ribcage pain in critically ill patients. *Med Intensiva*. 2014; 38: 463-465. <https://goo.gl/EAXi9p>
- Parras T. Case series: serratus plane block for rib fracture analgesia. *ESRA Academy*. 2015; 3: 105289. <https://goo.gl/HYxgLJ>
- Jadon A, Jain P, Motaka M. Serratus Anterior Plane Block failed to relieve Pain in Multiple Fractured Ribs: Report of Two Cases. *J Recent Adv Pain*. 2017; 3: 52-55. <https://goo.gl/N9Fnhl>
- Ueshima H, Kitamura A. Blocking of Multiple Anterior Branches of Intercostal Nerves (Th26) Using a Transversus Thoracic Muscle Plane Block. *Reg Anesth Pain Med*. 2015; 40: 388. <https://goo.gl/H9l7cx>
- Thomas KP, Sainudeen S, Jose S, Nadhari MY, Macaire PB. Ultrasound-Guided Parasternal Block Allows Optimal Pain Relief and Ventilation Improvement After a Sternal Fracture. *Pain Ther*. 2016; 5: 115-122. doi:10.1007/s40122-016-0050-5. <https://goo.gl/5o3dBf>
- Elsharkawy H, Saifullah T, Kolli S, Drake R. Rhomboid intercostal block. *Anaesthesia*. 2016; 71: 856-857. <https://goo.gl/KkGAT5>
- Forero M, Adhikary SD, Lopez H, Tsui C, Chin KJ. The Erector Spinae Plane Block: A Novel Analgesic Technique in Thoracic Neuropathic Pain. *Reg Anesth Pain Med*. 2016; 41: 621-627. <https://goo.gl/1rexYH>



41. Jadon A, Jain P, Sinha N. The Erector Spinae Plane Block for Postoperative Analgesia in Abdominoplasty -ACase Report. *BAOJ Anesthesia & Clinical Research* 2017; 1: 001.
42. Chin KJ, Adhikary S, Sarwani N, Forero M. The analgesic efficacy of pre-operative bilateral erector spinae plane (ESP) blocks in patients having ventral hernia repair. *Anaesthesia*. 2017; 72: 452-460. <https://goo.gl/iCLW3N>
43. Ishizuka K, Sakai H, Tsuzuki N, Nagashima M. Topographic anatomy of the posterior ramus of thoracic spinal nerve and surrounding structures. *Spine*. 2012; 37: 817-22. <https://goo.gl/SttpKX>
44. Sloan JP, Muwanga CL, Waters EA, Dove AF, Dave SH. Multiple rib fractures. transcutaneous nerve stimulation versus conventional analgesia. *J Trauma*. 1986; 26: 1120-1122. <https://goo.gl/IFhnDy>
45. Oncel M, Sencan S, Yildiz H, Kurt N. Transcutaneous electrical nerve stimulation for pain management in patients with uncomplicated minor rib fractures. *Eur J Cardiothorac Surg*. 2002; 22: 13-17. <https://goo.gl/00VBpB>
46. Ingalls NK, Horton ZA, Bettendorf M, Frye I, Rodriguez C. Randomized, double-blind, placebo-controlled trial using lidocaine patch 5% in traumatic rib fractures. *J Am Coll Surg*. 2010; 210: 205-209. <https://goo.gl/QqwMQp>
47. Fabricant L, Ham B, Mullins R, Mayberry J. Prolonged pain and disability are common after rib fractures. *Am J Surg*. 2013; 205: 511-515. <https://goo.gl/xIhSN>
48. Gordy S, Fabricant L, Ham B, Mullins R, Mayberry J. The contribution of rib fractures to chronic pain and disability. *Am J Surg*. 2014; 207: 659-662. <https://goo.gl/13H3H0>
49. Shimizu H, Kamiya Y, Nishimaki H, Denda S, Baba H. Thoracic paravertebral block reduced the incidence of chronic postoperative pain for more than 1 year after breast cancer surgery. *JA Clinical Reports* 2015; 1: 19. <https://goo.gl/KPjFrP>
50. Karmakar MK, Samy W, Li JW, Lee A, Chan WC, Chen PP, et al. Thoracic paravertebral block and its effects on chronic pain and health-related quality of life after modified radical mastectomy. *Reg Anesth Pain Med*. 2014; 39: 289-298. <https://goo.gl/GrL4Wq>