



International Journal of Cardiovascular Diseases & Diagnosis

Case Report

Multiple Organ Embolism Secondary to Heparin-Induced Thrombocytopenia after Intra-Aortic Balloon Pump Insertion -

Jiang Y. Wang, Xi Su*, Chen W. Liu, Chen YiXu, Zhi P. Zhang Dan Song,
JianPeng and Hua Yan

Department of cardiology, Wuhan Asia heart hospital, Wuhan, China

***Address for Correspondence:** Xi Su, Department of Cardiology, Wuhan Asia heart hospital,
Wuhan 430022, China, Tel: +8615172496706; E-mail: Yaxin_suxi@163.com

Submitted: 13 April 2017; **Approved:** 26 April 2017; **Published:** 02 May 2017

Citation this article: Su X, Wang JY, Liu CW, YiXu C, Zhang ZP, et al. Acute Myocardial Infarction
could Induce Aortic Dissection. Int J Cardiovasc Dis Diagn. 2017;2(1): 004-007.

Copyright: © 2017 Su X, et al. This is an open access article distributed under the Creative
Commons Attribution License, which permits unrestricted use, distribution, and reproduction in any
medium, provided the original work is properly cited.

ABSTRACT

Heparin-Induced Thrombocytopenia (HIT) is a highly prothrombotic disorder mediated by strong platelet-activating antibodies against multi molecular complexes of platelet factor4 and heparin, leading to consumptive thrombocytopenia and potentially devastating thromboembolic complications. Three alternative anticoagulants have been approved for the treatment of HIT: lepirudin, argatroban, and danaparoidsodium. We present a case of multiple organ embolism secondary to heparin-induced thrombocytopenia after IABP insertion in a cardiac shock secondary to acute myocardial infarction and our first experience with the use of a novel oral anticoagulant, rivaroxaban, to treat a case of HIT-associated thrombosis after IABP insertion.

Key words: Multiple organ embolism; Heparin-induced thrombocytopenia; Intra-aortic balloon pump; Rivaroxaban

CASE REPORT

A 48-year-old man presented to the emergency department of Wuhan Asia Heart Hospital with a recent onset of chest pain within a week. Electrocardiography performed on arrival revealed anterior Q-wave. The initial troponin I concentration was 16.398 ng/mL (reference range, 0-0.04 ng/mL) and a platelet count of 225,000 cells/mm³ (reference range, 100,000 to 300,000 cells/mm³). While the patient experienced extreme chest pain at the time of hospitalization. At the time his heart rate 132 beats/min, blood pressure 70/50 mmHg, there was not a thoracoabdominal bruit. Because the patient's hemodynamic status continued to worsen, an IABP was inserted immediately, antithrombotic strategies: aspirin, ticagrelor, and unfractionated heparin (Load 2000 u, 14 u/min, maintain APTT 60-80 seconds, until the IABP is removed). The ten minutes after IABP insertion, the patients' heart rate and blood pressure back to normal and patients with chest pain symptoms disappear. Due to the patient and family to refuse emergency percutaneous coronary intervention, so we mainly through enhancing drugs control symptoms of myocardial ischemia. After an uneventful hospital stay, the patient was discharged home on IABP insertion day 7 with a platelet count of 220,000 cells/mm³.

On IABP insertion day 8, the patient came to the emergency department with reports of dyspnea and chest pain and flank abdominal pain and slurred speech and right lower limb claudication. The platelet count on readmission, 5 days after the last heparin exposure, was 78,000 cells/mm³, and it continued to decrease to a nadir of 26,000 cells/mm³ on IABP placement day 10. Anti-platelet factor4-heparin antibodies were tested by a rapid lateral-flow immunoassay (STic EXPERT HIT; DiagnosticaStago SAS, Asni_eres, France), which yielded a strongly positive result, and the diagnosis of HIT was highly suspected. Abdominal computed tomography (ct) scan revealed the liver, kidney and spleen of infarct (Figure 1A-D). Head computed tomography (ct) scan revealed a multiple lacunar infarction (Figure 2A, B). Cerebrovascular computed tomography angiography revealed nonobstructive disease and no thrombosis (Figure 3). Coronary artery computed tomography angiography revealed the critical stenosis of the mid-LAD and the occlusion of middle of the mid-RCA (Figure 4 A-D). Bilateral lower extremity arteries computed tomography angiography revealed nonobstructive disease and no thrombosis in left lower limb arteries and the critical stenosis of the right plantar artery (Figure 5), and the corresponding distal toes ischemic gangrene (Figure 5). In view of the lack of argatroban availability in the hospital and the surrounding facilities, the patient was started on rivaroxaban at the dosage of 15 mg twice

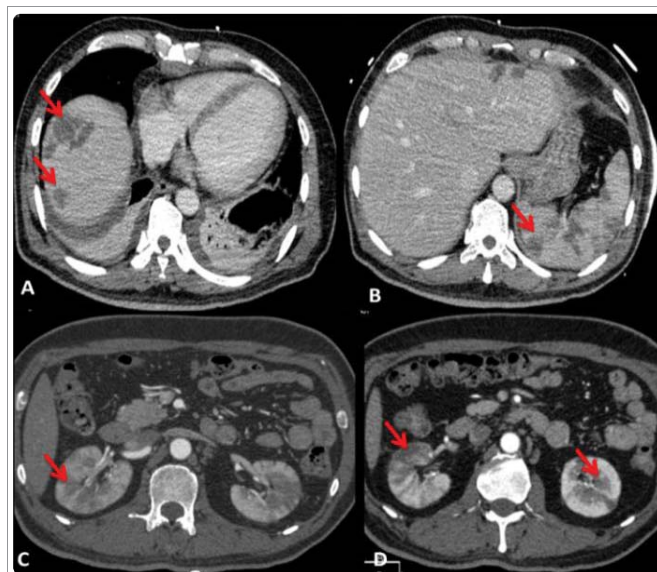


Figure 1a-d: A to D, Abdominal computed tomography (ct) scan revealed the liver, kidney and spleen of infarct (red arrow).

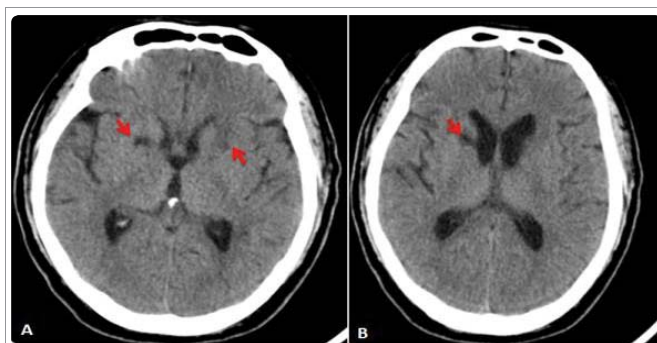


Figure 2a,b: A to B, Head computed tomography (ct) scan revealed a multiple lacunar infarction (red arrow).

daily then 20 mg daily. He had a gradual recovery and was finally discharged home with a platelet count of 150,000 cells/mm³. The platelet count reached 208,000 cells/mm³, and no serious bleeding complications had been noted by then. In the end, the patients discharged smoothly.

The case is one of multiple organ embolism secondary to heparin-induced thrombocytopenia after IABP insertion in a cardiac shock secondary to acute myocardial infarction. The diagnosis of HIT in this population remains a difficult one for several reasons. First,

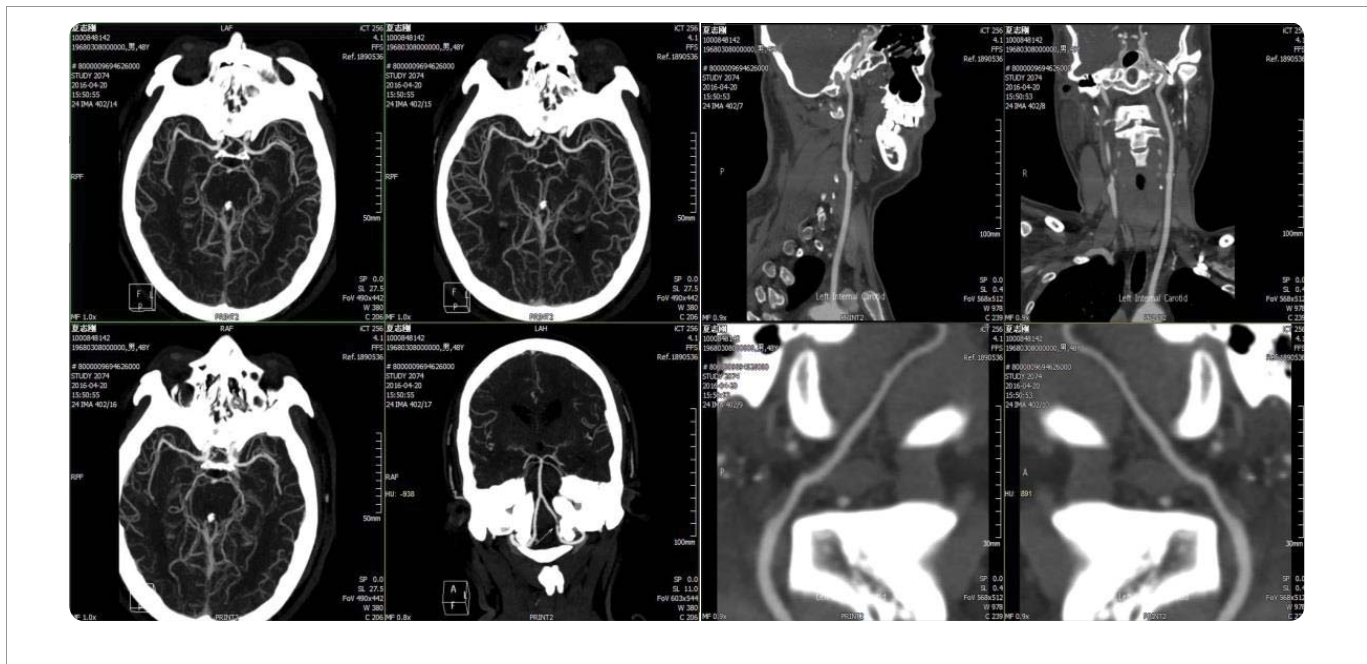


Figure 3: Cerebrovascular computed tomography angiography revealed nonobstructive disease and no thrombosis.

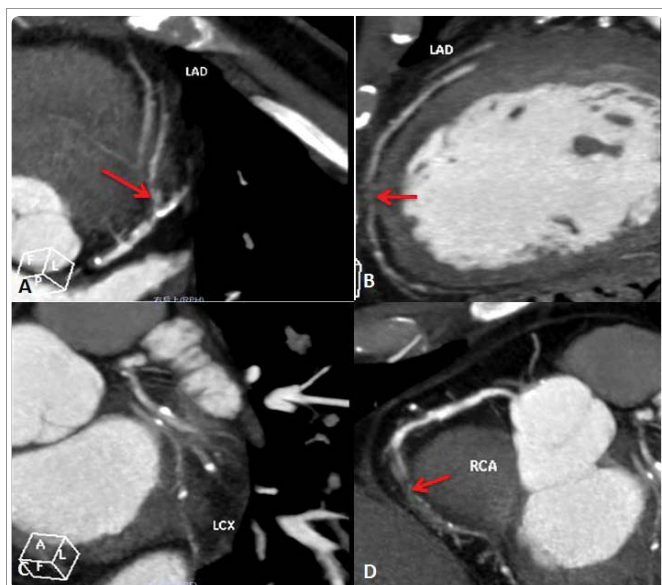


Figure 4a-d: A to D, Coronary artery computed tomography angiography revealed the critical stenosis of the mid-LAD and the occlusion of middle of the mid- RCA (red arrow).

thrombocytopenia is a common adverse effect of the IABP and a major decrease in platelet count by 30% to 50% occurs universally during the first 3 days after the IABP insertion and can persist beyond the first 9 days [1-2]. In addition, as many as 25% to 70% of patients have development of anti-platelet factor 4-heparin antibodies during the first 10 days after among patients who received heparin, but only a minority of these patients have development of clinically evident HIT [3]. Unfortunately, we had no access to washed-platelet functional assays, such as the carbon 14-labeled serotonin release assay; nevertheless, our patient had a high pretest probability for

HIT (a score of 7 according to the 4Ts scoring system) [4], along with a positive antibody test result, and so we decided to initiate alternative nonheparin anticoagulation because delays in treatment are associated with an initial 5% to 10% daily risk of thrombosis, amputation, or death. Currently approved parenteral direct thrombin inhibitors were not available at that time in our institution, however, and we therefore resorted to using rivaroxaban in the management of our patient, consistent with the previously reported [5].

Rivaroxaban is an oral, direct factor X inhibitor that has shown efficacy in the treatment of venous and arterial thromboembolism. The key advantages of its use for the treatment of HIT include ease of administration, absence of a need for laboratory monitoring, longer half-life and lower cost relative to parenteral agents. Moreover, it obviates the need for a warfarin–direct thrombin inhibitor overlap period and thus is expected to reduce the length of hospitalization [6]. After initiation of rivaroxaban treatment, careful attention is necessary, not only to bleeding but also to potential worsening of thrombocytopenia, because there have been rare reports of thrombocytopenia with novel oral anticoagulant use [7].

DECLARATIONS

Authors' contributions

Jiang-you wang and xi su analyzed and interpreted patient data. Jiang-you wang and xi su wrote the article and both authors read and approved the final manuscript.

CONSENT

Written informed consent was obtained from the patient for publication of this case report and accompanying images. A copy of the written consent is available for review by the Editor-in-Chief of this journal.

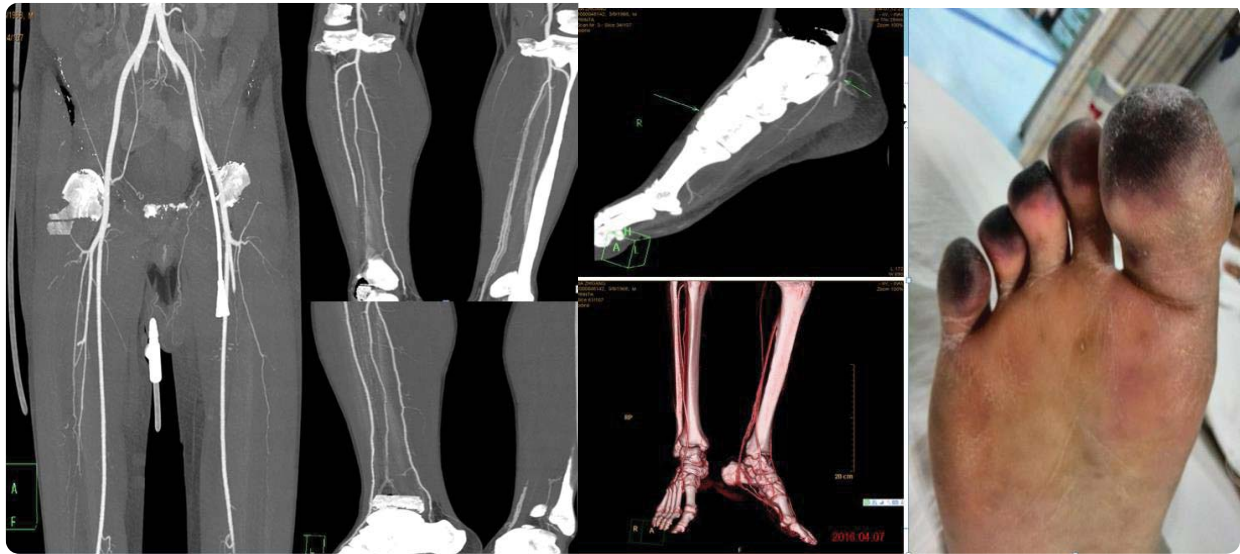

Figure 5: Bilateral lower extremity arteries computed tomography angiography revealed nonobstructive disease and no thrombosis in left lower limb arteries and the critical stenosis of the right plantar artery and the corresponding distal toes ischemic gangrene.

REFERENCES

- Roy SK, Howard EW, Panza JA, et al. Clinical implications of thrombocytopenia among patients undergoing intra-aortic balloon pump counter pulsation in the coronary care unit. *ClinCardiol* 2010; 33: 30-5. <https://goo.gl/xUP2eC>
- Boudoulas KD, Bowen T, Pederzoli A, Pfahl K, Pompili VJ, Mazzaferri EL Jr. et al. Duration of intra-aortic balloon pump use and related complications. *Acute Card Care* 2014; 16: 74-7. <https://goo.gl/OeHcPI>
- Pouplard C, May MA, Iochmann S, Amiral J, Vissac AM, Marchand M, et al. Antibodies to platelet factor 4-heparin after cardiopulmonary bypass in patients anticoagulated with unfractionated heparin or a low-molecular-weight heparin: clinical implications for heparin-induced thrombocytopenia. *Circulation* 1999; 99: 2530-6. <https://goo.gl/zB1GIH>
- Cuker A, Gimotty PA, Crowther MA, Warkentin TE. et al. Predictive value of the 4Ts scoring system for heparin-induced thrombocytopenia: a systematic review and meta-analysis. *Blood* 2012; 120: 4160-7. <https://goo.gl/mhJ7mA>
- Abouchakra L, Khabbaz Z, Abouassi S, Badaoui G. Rivaroxaban for treatment of heparin-induced thrombocytopenia after cardiac surgery: A case report. *J ThoracCardiovascSurg* 2015; 150:19-20.
- Linkins LA, Warkentin TE, Pai M, et al. Design of the rivaroxaban for heparin-induced thrombocytopenia study. *J Thromb Thrombolysis* 2014; 38: 485-92. <https://goo.gl/O8EtcY>
- Mima Y, Sangatsuda Y, Yasaka M, Wakugawa Y, Nagata S, Okada Y, et al. Acute thrombocytopenia after initiating anticoagulation with rivaroxaban. *Intern Med* 2014; 53: 2523-7. <https://goo.gl/ZyebDz>