



International Journal of Case Reports & Short Reviews

Case Report

Case of Spontaneous Live Unilateral Tubal Twin Ectopic Gestation - @

Maheshgir S Gosavi*

Siraj Hospital, Senior Consultant, Thane, India

***Address for Correspondence:** Maheshgir S Gosavi, Siraj Hospital, Vanjarpatti Naka, Bhiwandi, Thane, India, Tel: +910-252-225-3200/+918-693-027-439;
E-mail: raddon84@rediffmail.com; raddon84@gmail.com

Submitted: 12 December 2017; **Approved:** 20 March 2018; **Published:** 21 March 2018

Cite this article: Gosavi MS. Case of Spontaneous Live Unilateral Tubal Twin Ectopic Gestation. Int J Case Rep Short Rev. 2018;4(1): 012-014.

Copyright: © 2018 Gosavi MS. This is an open access article distributed under the Creative Commons Attribution License, which permits unrestricted use, distribution, and reproduction in any medium, provided the original work is properly cited.



ABSTRACT

Ectopic pregnancy is a common medical problem and it pose a serious diagnostic and therapeutic challenge in the obstetrics as the presenting symptoms and signs vary widely between patients. Unilateral twin tubal pregnancy is quite rare with a reported incidence of 1:200 ectopic pregnancies. It was first described in 1891 by De Ott .I present a case of successful management of spontaneous live right tubal ectopic pregnancy with no history of assisted reproductive techninique fertilization or pelvic inflammatory disease . Twin ectopic pregnancy, even though rare, must be looked for on ultrasound scanning with increasing incidence of pelvic inflammatory disease because of the potential mortality and morbidity associated with this condition.

Keywords: Transvaginal sonography; Live tubal ectopic; Laparoscopic salpingostomy

INTRODUCTION

Ectopic pregnancy is a common medical problem and it pose a serious diagnostic and therapeutic challenge in the obstetrics as the presenting symptoms and signs vary widely between patients. The incidence of such cases has been increasing over the past. There are multiple factors that contribute to the relative risk of ectopic pregnancy such as a history of tubal surgery, conception after tubal ligation, using fertility drugs and assisted reproductive technology [1]. The unilateral twin tubal pregnancy is quite rare with a reported incidence of 1:200 ectopic pregnancies [2]. It is a rare condition, first described by De Ott [3]. The present report describes a successful management of spontaneous live right tubal ectopic pregnancy with no history of assisted reproductive techninique fertilization or pelvic inflammatory disease. Twin ectopic pregnancy, even though rare, must be looked for on ultrasound scanning with increasing incidence of pelvic inflammatory disease because of the potential mortality and morbidity associated with this condition.

CASE PRESENTATION

A 35 year old female, came to casualty at midnight with pain in abdomen since three days with 8 weeks of amenorrhea and bleeding per vaginum since morning .She had one living issues with full term normal deliveries. She had history of two spontaneous abortions. Upon examination, her vitals were stable. Abdomen examination was unremarkable .Upon per vaginum examination the cervical movement was tender, the uterus was bulky and soft, and bogginess and tenderness were felt in the right adnexa. However, her urine pregnancy test was positive.

Ultrasonography with doppler study showed a uterus of 8.3 x 5.4 x 4.2 cms with endometrial thickness of 10 mm and there was evidence of large heterogenous lesion in the right adnexa of a size 7.1 x 5.1 cms, with sac like structure within which two foetal poles measuring 1.4 cm = 7 weeks and five days .Fetal cardiac activity was appreciated. Mild free fluid was seen in the abdomen. An impression of live twin ectopic pregnancy in the right adnexa was made with mild free fluid in an abdomen. A pseudosac like structure was noticed in endometrial cavity .Both ovaries were visualised separately from the right adnexal mass. Preoperative bHCG level was 1732 mIU/ml and Progesterone level was 9 ng/ml.

In view of the Twin live ectopic pregnancy she was immediately operated. Intraoperatively, the ampullary part of the right fallopian tube was found showed a sac like structure. A right side salpingostomy was done. She was discharged on the 7th day. On cut section of the sac there was evidence of two embryos Pathological evaluation of the surgical specimen showed a diamniotic monochorionic twins pregnancy within the fallopian tube and measurement of the twin fetuses estimated their gestational age at 7 weeks

DISCUSSION

The incidence of ectopic pregnancies has been increasing steadily since 1970s [4]. Based on the changing pattern of clinical presentation, the gynecologist should pay special attention in suspected cases. All available methods of diagnosing should be used including ultrasonography and blood chemistry tests such as beta Human Chorionic Gonadotropin (hCG) level and progesterone [5]. There is evidence that the hCG level of twin tubal pregnancies is higher than that of a singleton tubal pregnancy [6]. Several factors are thought to increase the risk of ectopic pregnancy. Transvaginal ultrasonography is recommended for detailed evaluation of patient suspected of having ectopic pregnancies because of the superior resolution of uterine and adnexal structures.

In our case, the patient was symptomatic and transvaginal Sonography has shown to be effective in the diagnosis of live twin tubal pregnancy and extremely sensitive in the detection of free pelvic fluid. Trans abdominal ultrasonography was not able to diagnose the twin ectopic pregnancy. The pathogenesis of unilateral

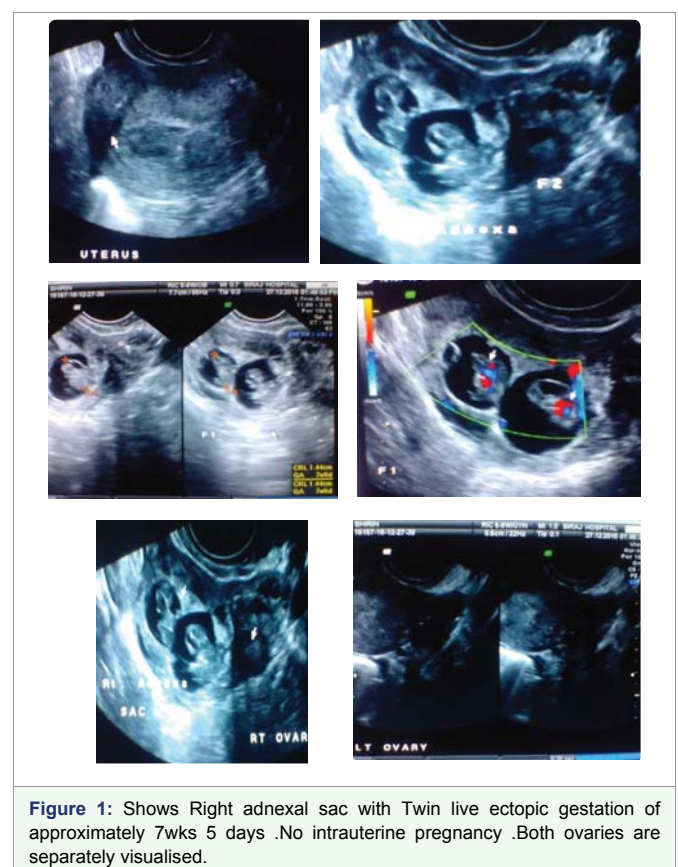


Figure 1: Shows Right adnexal sac with Twin live ectopic gestation of approximately 7wks 5 days .No intrauterine pregnancy .Both ovaries are separately visualised.

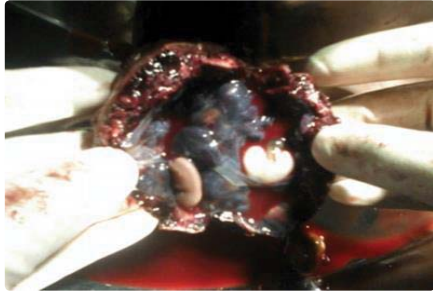

Figure 2: Pathological evaluation of the surgical specimen showed a diamniotic monochorionic twins pregnancy.

twin tubal pregnancy is not clear however several factors contribute to the occurrence of ectopic pregnancy. In the present case it was a spontaneous conception. No history of pelvic inflammatory disease, use of ovulatory drugs artificial reproductive technique was asked.

Treatment of an ectopic pregnancy depends on its clinical presentation, size, and complications, and may entail conservative, medical, or surgical intervention. There are a few reports of successful laparoscopic management of tubal twin pregnancy and operative laparoscopic salpingostomy [7]. In this case salpingostomy was preferred as to preserve the fertility. Salpingectomy is to be performed in cases of tubal rupture cases and has advantage that it removes the further risk of ectopic pregnancy. Salpingotomy preserves the fertility with the disadvantage of future risk of ectopic pregnancy [8].

Twin ectopic pregnancy, even though rare, must be looked for on ultrasound scanning, because of the potential mortality and morbidity associated with this condition [9].

CONCLUSION

A spontaneous unilateral twin tubal pregnancy can occur in patients who have no known predisposing factor. Early diagnosis

has made this disorder amenable to appropriate treatment. The high-resolution transvaginal sonography is very helpful in the diagnosis of this condition.

ACKNOWLEDGEMENTS

The author would like to thank the pathologists, gynaecologists who provided very important feedback with regard to the clinical aspect of this patient's condition. They contributed significantly to the patient being promptly diagnosed and receiving a high standard of care.

REFERENCES

1. Atye, Lam SL. Clinics in diagnostic imaging (106). Viable left tubal twin ectopic pregnancy. Singapore Med J. 2005; 46: 651-655. <https://goo.gl/bj1Ld8>
2. Breen JL. A 21-year survey of 654 ectopic pregnancies. Am J Obstet Gynecol. 1970; 106: 1004-1019. <https://goo.gl/RT2r25>
3. De Ott D. A case of unilateral tubal twin gestation. Annales de Gynecologie-etd'Obstetrique. 1891; 36: 304.
4. Shwayder JM, Mahoney V, Bersinger DE. Unilateral twin ectopic pregnancy managed by operative laparoscopy. A case report. J Reprod Med. 1993; 38: 314-316. <https://goo.gl/oY94US>
5. Murray H, Baakdah H, Bardell T, Tulandi T. Diagnosis and treatment of ectopic pregnancy Heather Murray. CMAJ. 2005; 173: 905-912. <https://goo.gl/ZznWYi>
6. Zakut H, Fiengold M, Lipnitzky W. Unilateral tubal pregnancy of twins. Clin Exp Obstet Gynecol. 1983; 10: 157-158. <https://goo.gl/c6oMcB>
7. Gassibe EF, Gassibe E. Laparoscopic management of ruptured tubal twin pregnancy. J Am Assoc Gynecol Laparosc 1996; 3. <https://goo.gl/FQunD3>
8. Mol F, Strandell A, Jurkovic D, Yalcinkaya T, Verhoeve HR, Koks CA, et al. The ESEP study: salpingostomy versus salpingectomy for tubal ectopic pregnancy; the impact on future fertility: a randomised controlled trial. BMC Womens Health. 2008; 8:11. <https://goo.gl/nX8Xa8>
9. Kakani A, Goel S, Shrivastava D, Shrivastava V. Unilateral tubal twin ectopic pregnancy: an unusual case. The Internet Journal of Gynecology and Obstetrics. 2012; 16: 2. <https://goo.gl/sSjrRr>