



Scientific Journal of Clinical Research in Dermatology

Case Report

Use of Calcium Hydroxylapatite for Augmentation of the Labia Majora and Mons Pubis - @

Jani AJ. van Loghem*

Private Practice, Netherlands

***Address for Correspondence:** J. Van Loghem, Private practice, Doctors Inc. Falckstraat 51, 1017VV Amsterdam, Netherlands, E-mail: jani@doctors-inc.com

Submitted: 03 March 2017; **Approved:** 27 March 2017; **Published:** 04 April 2017

Citation this article: van Loghem JAJ. Use of Calcium Hydroxylapatite for Augmentation of the Labia Majora and Mons Pubis. Sci J Clin Res Dermatol. 2017;2(1): 010-013.

Copyright: © 2017 van Loghem JAJ. This is an open access article distributed under the Creative Commons Attribution License, which permits unrestricted use, distribution, and reproduction in any medium, provided the original work is properly cited.



ABSTRACT

Introduction: Labia minora that protrude past the labia majora are aesthetically unsatisfactory to some women. Patient preference is for minimally invasive procedures with little or no downtime and minimal scarring. Fat grafts and crosslinked hyaluronic acid have been used to treat the labia majora and mons pubis for aesthetic improvement of the external female genitalia. Here, the author describes a simple and effective technique for addressing hypotrophic labia majora by injecting diluted Calcium Hydroxylapatite (CaHA).

Case Presentation: A 22-year-old post-labiaplasty patient with a protruding clitoral hood was treated with 6 ml diluted CaHA in two treatment sessions with a time interval of 6 weeks using non-traumatic cannulas. At 3 months a significant improvement in the appearance of the external genitalia was observed. No serious side effects were noted and results lasted beyond 12 months.

Discussion: The rationale for using CaHA is twofold: CaHA-induced neocollagenesis improves skin laxity and the product's volumizing capacity corrects volume deficiency. Knowledge of local anatomy is crucial to avoid complications.

Conclusion: The use of CaHA can be a valuable, well-tolerated and long-lasting addition to available treatments for the aesthetic improvement of the female genitalia. Further studies are necessary to evaluate long-term safety and efficacy in larger cohorts.

INTRODUCTION

Female sexual enhancement is defined as anything that enhances a woman's sexuality, and includes any procedure that improves a woman's sexual self-image. With explicit images in magazines and videos, as well as apparel, the female genitalia is much more on display. As a result, some modern women may be self-conscious of the appearance of their external genitalia and seek medical procedures to improve them [1].

Labia minora that protrude past the labia majora can be regarded as aesthetically and functionally unsatisfactory and may lead some women to undergo surgical reduction of the labia minora [2,3]. Surgical procedures give patients the option to modify, enhance, or improve the appearance of their external genitalia. However, surgery of the labia majora has been found to be complicated by bleeding and considerable down time [4]. Patients nowadays are more demanding and generally prefer less invasive procedures with minimal or no downtime and minimal scarring, as is evident from 2015 statistics from The American Society for Aesthetic Plastic Surgery (ASAPS). They reported a total of 8,745 labiaplasty procedures performed in 2015, with a dramatic increase (more than 15%) compared to the previous year [5].

During the aging process, the labia majora lose volume and the skin becomes laxer and starts to show wrinkles. Fat grafts have been utilized in plastic surgery for both reconstructive and aesthetic labia majora procedures [2], but more recently, minimally-invasive crosslinked hyaluronic acid has been used to treat the labia majora and mons pubis for aesthetic improvement of the external female genitalia [6]. Dermal fillers have a broad range of use in dermatology and aesthetic medicine including facial rejuvenation and volume restoration, the correction of wrinkles, facial defects, acne scars, and for lipodystrophy, including HIV-associated lipoatrophy. They can be easily injected under the skin in a minimally-invasive fashion and dermatologists, plastic surgeons and other aesthetic practitioners are familiar with the use of fillers for the above indications.

In the Netherlands, calcium hydroxylapatite dermal filler (CaHA; Radiesse®, Merz North America, Inc., Raleigh, NC, USA) is approved for soft tissue augmentation, but there is currently no published literature describing the use of CaHA for general enhancement of the labia majora and mons pubis.

In this article, the author describes a simple and effective technique for addressing hypotrophic labia majora by injecting

diluted CaHA with a non-traumatic cannula. CaHA was chosen for this procedure because it has demonstrated long-lasting aesthetic effects [7], stimulates neocollagenesis [8], and has the ideal viscosity for precise sculpting [9].

CASE PRESENTATION

A 22-year old caucasian woman presented with hypotrophic labia majora and a protruding clitoral hood. In an effort to improve the appearance of her external genitalia, she had previously undergone surgical reduction of the labia minora. Post-operatively, she still complained of an aesthetically displeasing protrusion of her clitoral hood (Figure 1). On inspection, her labia majora were identified as hypotrophic and thus candidates for volumizing treatment with CaHA subdermal injections. The CaHA (3.0 ml syringe) was mixed with 0.6 ml of 2% lidocaine before injection according to the FDA-approved protocol [10], which includes a minimum of 10 passes back and forth to ensure homogenous mixing. A 7 cm, 22G cannula (TSK Labs) was used for subdermal infiltration of the CaHA. Before injection, the entry points for the cannula were marked 1 cm above the superior border of both labia majora and a local anesthetic (0.1 ml lidocaine 1% with adrenalin 1:200.000) was injected at the entry points for anesthesia and hemostasis. A 21G needle was used to make an opening through the skin and the 22G cannula was introduced through this aperture. Using a retrograde fanning technique, the CaHA was evenly distributed along both labia majora (1.5 ml each side) at the junction of the dermal-subdermal plane (Figure 1). To ensure correct injection depth, the skin was stretched in the direction of the cannula, while the flexibility of the cannula was used to point the tip towards the dermis while advancing. A rolling technique, where the syringe was rolled between thumb and index finger, was used to overcome any resistance to the trajectory of the cannula. The patient reported no discomfort during the procedure. After injection, the CaHA was manipulated to ensure homogenous distribution in the labia majora.

Immediately post-treatment the clitoral hood appeared significantly less protruding. There was no ecchymosis, but post-treatment swelling was observed, comparable to the swelling occurring after facial, neck or hand treatment with CaHA (Figure 2). The patient reported that the swelling lasted for approximately 1 day and that there was a gradual reduction in stiffness of the labia during the 6 weeks to the follow-up visit.

At the 6-week follow-up visit, a further 3.0 ml syringe of CaHA (mixed with lidocaine) was used to aesthetically improve the mons

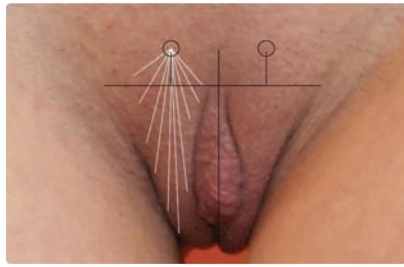


Figure 1: Schematic drawing of the fanning technique used in the first treatment. An entrance point approximately 1 cm superior to the superior end of the labia majora was selected for a retrograde fanning technique with a 7 cm 22G cannula. 1,5 ml of CaHA was used on each side.

pubis, in particular, the area directly superior to the clitoral hood to further hide the clitoral hood. An entrance point was selected in the midline approximately 2 cm inferior to the skin fold and pubic hairline. Using the same fanning technique, the area of the mons pubis and the superior part of the labia majora were treated (Figure 3).

Three months after the first treatment, the patient returned for a second follow-up visit. A significant improvement was observed and no further treatment was necessary. The stiffness in her labia majora had resolved. (see final before and after images in Figure 4).

DISCUSSION

As patients become more aware of the possibilities of aesthetic genital improvements using medical interventions, the demand for safe procedures with low downtime increases. Labia majora and mons pubis presentations that are unpleasing to a woman aesthetically may be the result of either congenital or age-related hypotrophy of adipose tissue and of skin laxity in these areas. CaHA is versatile filler that can correct both issues simultaneously: the CaHA-induced neocollagenesis improving skin laxity, and the gel correcting volume deficiency. The long duration of effect also makes CaHA a good choice for this indication. The product used in this study, Radiesse, consists of two components. The active component is synthetic calcium hydroxylapatite spheres of 25-45 µm in diameter (30% volume) suspended in a carboxymethyl cellulose (CMC) gel carrier (70%). After injection, the gel resorbs in approximately 3 months while the CaHA spheres attract and stimulate fibroblasts to produce collagen and elastin fibers. The volume of the resorbed gel is gradually replaced by newly-produced collagen fibers, resulting in a 1:1 correction when using the pure product without dilution [11,12]. In the current study, CaHA was diluted with lidocaine and therefore some reduction in the final result was expected after the lidocaine had diffused from the injection site.

CaHA provides a long-lasting effect of approximately 12 months, which is longer than most Hyaluronic Acid (HA) fillers, but shorter than lipofilling which can be permanent. As CaHA is a biostimulatory product, the result is dependent on the reaction of the patient's fibroblasts. In a post-menopausal women a lower level of neocollagenesis would be expected and therefore, predictability may be reduced in older age groups. Even though an advantage of HA fillers is that their effects can be reversed with hyaluronidase, two studies show that there are also successful methods of effectively treating inadvertent nodules after CaHA injection [13,14].

The volumizing technique described here in which non-traumatic

cannulas are used to treat the labia majora and the mons pubis is the same as that used in facial treatments. Anatomically the mons and labiae are relatively safe areas for treatment with non-traumatic cannulas, as long as the cannula is not forced into a superficially running artery. The vulva is supplied by the anterior labial arteries, branches of the external pudendal arteries, posterior labial arteries, and branches of the internal pudendal arteries. An adequate knowledge of their localization is fundamental to avoid inadvertent intraluminal infiltration with potentially severe complications (vascular occlusion, embolization) [15].

Other possible complications include those related to the product. However, as CaHA has the same molecular structure as the human mineral found in bone and teeth, the chance of foreign body granuloma formation is extremely low compared with HA fillers, whose molecules have been crosslinked to improve longevity [16]. For a rejuvenating effect on skin quality of the labia majora, chemical peels or lasers may be alternatives to CaHA and an additional aesthetic improvement in terms of pigmentation reduction may be observed that cannot be achieved with CaHA or HA injection. Lipofilling has also been shown to have positive effects on skin quality, probably



Figure 2: Typical swelling immediately post treatment.




Figure 3: 6 weeks after the first treatment. Schematic drawing of the fanning technique used in the second treatment. An entrance point approximately 2 cm inferior of the pubic hairline / skin fold of the mons pubis was selected for a retrograde fanning technique with a 7 cm 22G cannula. 1,5 ml of CaHA was used on each side.

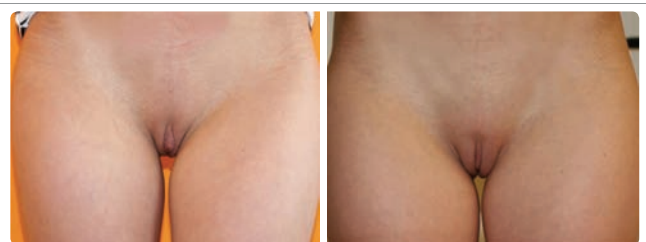

Figure 4: Before and 3 months post treatment with 6 ml of CaHA.

Table 1: Summary of advantages and disadvantages of CaHA for augmentation of labia majora and mons pubis compared with Hyaluronic Acid (HA) and lipofilling (fat) alternatives.

	CaHA	HA	Fat
Predictability	+	++	+/-
Longevity	+	+/-	++
Resorbability (antidote)	+/-	++	-
Product safety	++	+	++
Skin improvement	++	-	+
Natural look and feel	++	++	++
Downtime	+	+	-
Price	+	+/-	-

++: very good advantage, +: good advantage, +/-: neutral, -: disadvantage.

due to the effects of adipose-derived stem cells [17]. Although fat would feel the most natural, the large injection cannulas used in the lipofilling procedure mean that some fibrosis can be expected. HA and CaHA can be injected through very small injection cannulas and with a very gentle technique, resulting in less procedure-related fibrosis. Even though the CaHA-treated area in the current study was firm after 3 months, it felt natural to the patient. The downtime was acceptable (1-2 days of swelling), comparable to that observed following HA injections, and preferable to lipofilling where the downtime associated with both harvesting and grafting sites may take several weeks. CaHA is economic filler with high viscosity and elasticity, so that less product is required to achieve the end result compared with fillers with lower visco-elasticity [18]. Although the price per ml of fat might be lower, lipofilling procedures are generally more expensive due to factors such as facility regulations (e.g. class 1 surgical room), number of staff and length of the procedure.

A summary of the advantages and disadvantages of CaHA for augmentation of female genitalia are shown in Table 1. This case report only describes one patient, and even though the results are promising, more patients from different age groups should be evaluated to confirm the efficacy and longevity, as well as safety of CaHA for female genital enhancement.

CONCLUSION

Preliminary data indicate that CaHA may be a valuable, well-tolerated and long-lasting treatment option for aesthetic improvement of the female genitalia. Further studies are necessary to evaluate long-term safety and efficacy in larger cohorts.

REFERENCES

1. Liao LM, Creighton SM. Requests for cosmetic genitoplasty: how should healthcare providers respond? *BMJ*. 2007; 334: 1090-1092. <https://goo.gl/6E9Dbq>

2. Salgado CJ, Tang JC, Desrosiers AE. Use of dermal fat graft for augmentation of the labia majora. *J Plast Reconstr Aesthet Surg*. 2012; 65: 267-70. <https://goo.gl/6SytV8>

3. Vogt PM, Herold C, Rennekampff HO. Autologous fat transplantation for labia majora reconstruction. *Aesthetic Plast Surg*. 2011; 35: 913-5. <https://goo.gl/6yyx7Z>

4. Di Saia JP. An unusual staged labial rejuvenation. *J Sex Med*. 2008; 5:1263-7. <https://goo.gl/aBhTN3>

5. American Society for Aesthetic Plastic Surgery (ASAPS). Cosmetic surgery national data bank statistics 2015. 35: 1-24. <https://goo.gl/E1Ru3C>

6. Fasola E, Gazzola R. Labia majora augmentation with hyaluronic acid filler: technique and results. *Aesthet Surg J*. 2016; 36: 1155-63. <https://goo.gl/n3HRSL>

7. Silvers SL, Eviatar JA, Echavez MI, Pappas AL. Prospective, open-label, 18-month trial of calcium hydroxylapatite (Radiesse) for facial soft-tissue augmentation in patients with human immunodeficiency virus-associated lipodystrophy: one-year durability. *Plast Reconstr Surg*. 2006; 118: 34S-45S. <https://goo.gl/rWICS>

8. Berlin A, Cohen JL, Goldberg DJ. Calcium hydroxylapatite for facial rejuvenation. *Semin Cutan Med Surg*. 2006; 25: 132-7. <https://goo.gl/pCc0p0>

9. Sundaram H, Voigts B, Beer K, Meland M. Comparison of the rheological properties of viscosity and elasticity in two categories of soft tissue fillers: calcium hydroxylapatite and hyaluronic acid. *Dermatol Surg*. 2010; 36: 1859-65. <https://goo.gl/S3syDv>

10. Busso M. Calcium hydroxylapatite (Radiesse): safety, techniques and pain reduction. *J Drugs Dermatol*. 2009; 8: s21-3. <https://goo.gl/XMSmKV>

11. Coleman KM, Voigts R, Devore DP, Termin P, Coleman WP 3rd. Neocollagenesis after injection of calcium hydroxylapatite composition in a canine model. *Dermatol Surg*. 2008; 34: S53-S55. <https://goo.gl/g2S7qO>

12. Yutskovskaya YA, Kogan EA. Improved neocollagenesis and skin mechanical properties after injection of diluted calcium hydroxylapatite in the neck and décolletage: a pilot study. *J Drugs Dermatol* 2017; 16: 68-74. <https://goo.gl/4rwLSv>

13. Voigt R, Devore D, Grazer J. Dispersion of calcium hydroxylapatite accumulations in the skin: animal studies and clinical practices. *Dermatol Surg*. 2010; 36: 798-803. <https://goo.gl/2WXlqH>

14. Aguilera SB, Aristizabal M, Reed A. Successful treatment of calcium hydroxylapatite nodules with intralesional 5-fluorouracil, dexamethasone, and triamcinolone. *J Drugs Dermatol*. 2016; 15: 1142-43. <https://goo.gl/0pyGDG>

15. El-Khalawany M, Fawzy S, Saied A, Mohammed Al Said, Ahmed Amer, Bayoumi Eassa. Dermal filler complications: a clinicopathologic study with a spectrum of histologic reaction patterns. *Ann Diagn Pathol*. 2015; 19: 10-15. <https://goo.gl/C0BBYT>

16. Lemperle G, Gauthier-Hazan N. Foreign body granulomas after all injectable dermal fillers: Part 2. Treatment options. *Plast Reconstr Surg*. 2009; 123: 1864-73. <https://goo.gl/nSXBHv>

17. Tonnard P, Verpaele A, Peeters G, Hamdi M, Cornelissen M, Declercq H. Nanofat grafting: basic research and clinical applications. *Plast Reconstr Surg*. 2013; 132: 1017-26. <https://goo.gl/Bey1n1>

18. Moers-Carpi MM, Tufet JO. Calcium hydroxylapatite versus nonanimal stabilized hyaluronic acid for the correction of nasolabial folds: a 12-month, multicenter, prospective, randomized, controlled, split-face trial. *Dermatol Surg*. 2008; 34: 210-15. <https://goo.gl/xcZCt6>