



Scientific Journal of Clinical Research in Dermatology

Case Report

Early Malignant Syphilis Associated with Uveitis in Immunocompetent Patient: Case Report -

Thais Reginatto Nietzsche*, Fernanda Silveira Costa, Arles Martins Brotas, Maria De Fatima Guimaraes Scotelaro Alves, Alexandre Carlos Gripp, Cibele Apostolos Pereira and Daniel Lago Obadia

Department of Dermatology/ Rio de Janeiro State University, Rio de Janeiro, Brazil

***Address for Correspondence:** Thais Reginatto Nietzsche, Rio De Janeiro State University (UERJ) / Pedro Ernesto University Hospital (HUPE). Boulevard 28 de Setembro, 77 - Vila Isabel, Rio de Janeiro – RJ. Zip-code: 20551-030, Brazil, Tel: +55 2-1 286-88478; E-mail: thaisnietzsche@hotmail.com

Submitted: 22 January 2018; **Approved:** 08 February 2018; **Published:** 13 February 2018

Cite this article: Nietzsche TR, Costa FS, Brotas AM, Guimaraes Scotelaro Alves MDF, Gripp AC, et al, Early Malignant Syphilis Associated with Uveitis in Immunocompetent Patient: Case Report. Sci J Clin Res Dermatol. 2018;3(1): 001-003.

Copyright: © 2018 Nietzsche TR, et al. This is an open access article distributed under the Creative Commons Attribution License, which permits unrestricted use, distribution, and reproduction in any medium, provided the original work is properly cited.

ABSTRACT

Introduction: malignant syphilis is an uncommon form of secondary syphilis. This presentation usually occurs in immunocompromised patients, especially in those ones infected by human immunodeficiency virus (HIV). However, it is known that it might exceptionally affect individuals with normal immune response.

Case report: in this manuscript, we report a case with ocular involvement in a male immunocompetent patient. He had extended skin lesions and conjunctival hyperemia on the right eye. After the laboratorial investigation we confirmed syphilis and excluded human immunodeficiency virus (HIV) infection. Considering he had uveitis, the case was conducted as neurosyphilis and the treatment was made with Ceftriaxone, followed by excellent clinical response.

Conclusion: given the increasing number of cases of syphilis, in patients with polymorphic skin lesions associated with systemic symptoms, it is important to exclude immunosuppression and even in immunocompetent subjects this condition should always be a differential diagnosis.

Keywords: Malignant Syphilis; Immunocompetent; Uveitis

INTRODUCTION

Malignant syphilis is an uncommon form of secondary syphilis characterized by an exuberant dermatological picture with ulcer-necrotic skin lesions, which are typically associated with systemic signs and symptoms. This presentation usually occurs in immunocompromised patients, especially in those ones infected by Human Immunodeficiency Virus (HIV). However, it is known that it might exceptionally affect individuals with normal immune response. In the current context of marked exposure and increasing incidence of syphilis in several countries, attention should be paid to the increase in malignant syphilis incidence. We present a case with ocular involvement in a male immunocompetent patient.

CASE REPORT

A 30-year-old male patient was referred to the Dermatology Service because of the painful erythematous plaques three-month history, initially on the trunk and upper limbs with posterior spread to the face and scalp. Some lesions have progressed to ulcerations. He also had fever, hyporexia, asthenia and myalgia. In addition, in the previous week he complained of visual turbidity and conjunctival hyperemia on the right eye. It was a previously healthy individual, who referred to have unprotected sexual intercourse with a fixed partner. One month after the beginning of the signs and symptoms, having already sought medical attention, the patient was submitted to laboratory evaluation, including viral and syphilis serologies all negative ones, especially the ones regarding anti-HIV antibody testing and Venereal Disease Research Laboratory (VDRL).

At the physical examination, the patient seemed to be at a good general condition and there was no report of fever. However, he had multiple erythematous, mostly infiltrated, papulo-nodular cutaneous lesions, in addition to some ulcero-crusts having necrotic aspect. They predominated in the trunk and upper limbs. We also emphasize a plaque with central ulceration covered by meliceric crusts and some blood spots on the right shoulder (Figure 1). The palmoplantar regions were spared. There were also no visible oral and genital mucosal lesions. Ophthalmologic evaluation showed anterior uveitis in the right eye.

However, the neurological examination was normal. A skin biopsy was performed that demonstrated psoriasiform and lichenoid dermatitis, composed of lymphocytes, plasma cells and perivascular histiocytes (Figure 2). Two months after the first laboratory tests, repeated viral serologies, once again negative, with emphasis on

HIV Polymerase Chain Reaction (PCR), also negative. However, the serology for syphilis this time was positive, with VDRL titre at 1/256 and Treponema Pallidum Haemagglutination test (TPHA) reagent.

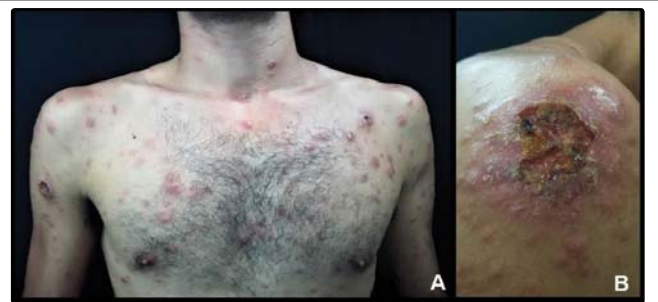

Figure 1: (A) Papulo-nodular erythematous lesions, some ulcero-crusted in the trunk and upper limbs. (B) Plaque with central ulceration covered by meliceric and hematic crusts on the right shoulder.

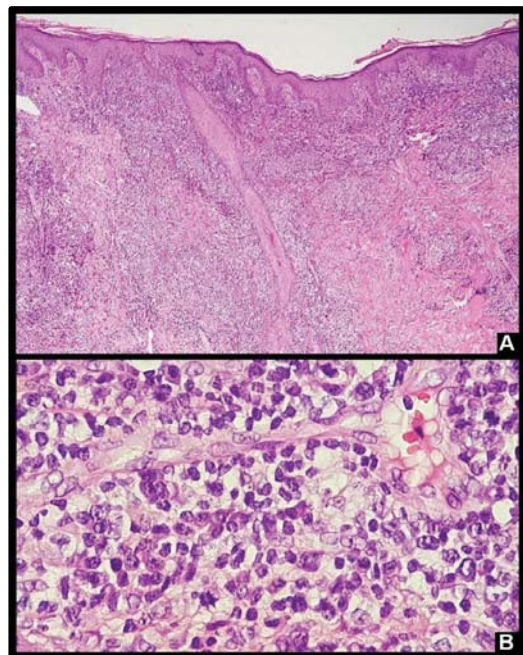


Figure 2: (A) Psoriasiform and lichenoid dermatitis. (B) Perivascular infiltrate with predominance of lymphocytes and plasma cells.



Other laboratory tests and Cerebrospinal Fluid (CSF) were normal. The patient was allergic to penicillin and undertook a treatment with Ceftriaxone 2g IV / day for 14 days, with excellent clinical response and surprising drop in VDRL titration (1/16) at the end of the antibiotic therapy period.

DISCUSSION

Early malignant syphilis is a rare presentation of secondary syphilis, originally described by Bazin in 1859 as a nodular variant of syphilis. Often associated with HIV co infection. Malnutrition, abusive alcohol consumption and concomitance with debilitating diseases are other possible predisposing factors [1].

Its pathogenesis is unknown, but it is seemingly more related to the host than to its causal agent, *Treponema pallidum*. This theory is based on the fact that patients with malignant syphilis usually acquire the infection of individuals with classical manifestations of the disease which has milder clinical findings [2]. This would justify the fact that it is more common in immunocompromised patients. Notwithstanding, it should be noted that it is not exclusive to these ones, as we may notice it in our patient.

This infection is characterized by atypical, crusty and disseminated atypical cutaneous lesions associated with general nonspecific symptoms that may delay diagnosis [3].

The following criteria for its presumptive diagnosis were proposed by Fisher et al in 1969: compatible clinical and histopathological changes, Jarisch-Herxheimer reaction, dramatic response to antibiotic therapy and serological tests for positive syphilis in high titers [4].

Due to the importance of the serological tests for the diagnosis, we draw our attention to the Prozone effect, which occurred in the described case, and consists of a false negative initial non-treponemal test result as a consequence of antibodies in undiluted serum excess [5]. Therefore, before strong clinical suspicion, the diagnosis of syphilis should not be ruled out after an initial negative examination. It is important in such cases to consider repeating VDRL with additional dilution and adding a treponemal test to laboratory investigations.

The malignant syphilis treatment is the same as for secondary syphilis and, according to the Center for Disease Control and Prevention (CDC) guidelines, it consists of a single dose of penicillin G Benzathine 2.4 million intramuscularly units [6].

When there is ocular involvement, treatment should be done as in a neurosyphilis case. The drug of choice is crystalline penicillin G

18 to 24 intravenously million units / day for 10 to 14 days. In cases of documented allergy or unavailability of this drug, daily intravenous Ceftriaxone 2g is used, also for 14 days [6, 7].

Ocular involvement has already been described in patients with this form of syphilis; however, they were HIV positive ones. After a literature review, only one case by De Unamuno Bustos et al has been already reported of a previously healthy patient with early malignant syphilis and ophthalmologic alterations [8].

This is, therefore, the second case of early malignant syphilis with ocular manifestation in an immunocompetent patient described up to the present moment.

CONCLUSION

Given the increase in the number of cases of syphilis, dermatologists and clinicians should be aware of the malignant cases in order to allow early diagnosis and treatment, thus, reducing their morbidity and dissemination.

In patients with polymorphic skin lesions associated with systemic symptoms, it is important to exclude immunosuppression and even in immunocompetent subjects this condition should always be a differential diagnosis.

REFERENCES

1. Requena CB, Ocanha JP, Marques MEA, Orasmo CR, Barraviera SRCS, Marques SA. Malignant syphilis in an immunocompetent female patient. *An Bras Dermatol*. 2014; 89: 970-972. <https://goo.gl/Qk9NCZ>
2. Kumar B, Muralidar S. Malignant syphilis: a review. *AIDS Patient Care STDS*. 1998; 12: 921-925. <https://goo.gl/gV25fA>
3. Corti M, Solari R, Carolis LD, Figueiras O, Vittar N, Maronna E. Sifilis maligna em un paciente con infeccion por VIH. Presentacion de un caso y revision de la literatura. *Rev Chilena Infectol*. 2012; 29: 678-681. <https://goo.gl/posrg2>
4. Fisher DA, Chang LW, Tuffanelli DL. Lues Maligna: Presentation of a Case and a Review of the Literature. *Arch Dermatol*. 1969; 99: 70-73. <https://goo.gl/cVnxhk>
5. Liu LL, Lin RR, Tong ML, Zhang HL, Huang SJ, Chen YY, et al. Incidence and risk factors for the prozone phenomenon in serologic testing for syphilis in a large cohort. *Clin Infect Dis*. 2014; 59: 384-389. <https://goo.gl/1jdnrk>
6. Workowski KA, Bolan GA. Centers for Disease Control and Prevention. Sexually transmitted diseases treatment guidelines, 2015. *MMWR Recomm Rep*. 2015; 64: 1-137. <https://goo.gl/aBA1aS>
7. Gaudio PA. Update on ocular syphilis. *Curr Opin Ophthalmol* 2006;17:562-566. <https://goo.gl/uzT9Sh>
8. De Unamuno Bustos B, Sanchez RB, Carazo JL, de Miguel VA. Malignant syphilis with ocular involvement in an immunocompetent patient. *Int J Dermatol*. 2014; 53: 240-316. <https://goo.gl/ZQpo5d>