



# International Journal of Clinical Endocrinology

## Case Report

# Hypercalcemic Crisis with Acute Pancreatitis - unusual Presentation of Parathyroid Cyst - @

**Lalit K. Bansal\*, Lalit Aggarwal and Saurabh Shekhar**

*Ram Manohar Lohia Hospital and Post Graduate Institute of Medical Education and Research, New Delhi*

**\*Address for Correspondence:** Lalit K. Bansal, Ram Manohar Lohia Hospital and Post Graduate Institute of Medical Education and Research, New Delhi, Tel: +813-036-8883;  
E-mail: dr.lkbansal@gmail.com

**Submitted: 26 March 2018; Approved: 28 April 2018; Published: 28 May 2018**

**Cite this article:** Bansal LK, Aggarwal L, Shekhar S. Hypercalcemic Crisis with Acute Pancreatitis - unusual Presentation of Parathyroid Cyst. Int J Clin Endocrinol. 2018;2(1): 019-021.

**Copyright:** © 2018 Bansal LK, et al. This is an open access article distributed under the Creative Commons Attribution License, which permits unrestricted use, distribution, and reproduction in any medium, provided the original work is properly cited.

## ABSTRACT

The incidence of parathyroid cysts in the general population is not known precisely. It very low in a large series of consecutive neck USG (0.075%) and a prevalence of 3% was found in patients operated for cervical mass or hyperparathyroidism [1]. Moreover, a few series have reported on the incidence of functional cysts, which may vary from 10 to 33% [2]. Symptomatic parathyroid cyst is a rare entity. Hypercalcemic crisis with features of acute pancreatitis in parathyroid cyst is also rare. Aggressive and appropriate medical and surgical management is required in these cases.

Here we are describing a case of hyperparathyroidism with features of hypercalcemia with acute pancreatitis. Later he was diagnosed as right inferior parathyroid cyst for which excision was done and gradually patient was relieved from features of hypercalcemia and acute pancreatitis.

## INTRODUCTION

Parathyroid cysts are rare clinical and pathological entities representing 0.5% to 1.0% of parathyroid lesions and less than 1% of all cystic neck masses [1]. So far very few cases have been reported in the literature. Parathyroid cysts are categorized as functioning and nonfunctioning depending on their ability to secrete Parathyroid Hormone (PTH).

## CASE SUMMARY

40 year male admitted in surgical emergency with complaint of severe abdominal pain radiating to back since 2 days. He is also complaining of generalized weakness with fatigability with bone pain since one month. Patient was non alcoholic and also there is no history of any gall stone disease or jaundice in past. There is no history of any medicine intake. Family history was insignificant for any similar illness or other endocrine dysfunction. Past surgical history was negative.

On examination 2x2 cm palpable swelling which was nonmobile and soft in consistency present in right neck region inferior aspect. He has also tenderness in epigastric region on abdomen examination.

On blood investigation his serum calcium was high (14.5 mg/ dl) and phosphate level was low (2.3 mg/ dl). Serum parathyroid level was very high (579 pg/ ml). Serum amylase level was 979 and serum lipase level was 1269 which is very high. Other blood investigations were within normal range.

USG neck shows 2x2 cm cystic lesion was found in right neck below right lobe of thyroid inferior aspect. USG abdomen shows hypoechoic lesion in head of pancreas with bulky pancreas and fat stranding suggestive of acute pancreatitis. There is no evidence of any gall stone or renal calculi. Sestamibi scan does not show any focal uptake. Diagnosis of hyperfunctioning parathyroid cyst with hypercalcemic crisis with acute pancreatitis due to hypercalcemia was made in view of above mentioned findings.

After proper hydration and conservative management of hyperparathyroidism surgery was planned. Intraoperatively 2x2 cm cystic parathyroid gland was identified which was aspirated (Figure 1) initially and aspirated fluid sent for PTH level. PTH level of the fluid was very high (in thousands). Cyst was excised carefully and sent for histopathology.

Histopathology revealed parathyroid tissue with clear fluid with very high parathyroid hormone content within it. Gradually serum calcium and phosphate level were came out to be in normal range and patient relieved from sign and symptoms of hypercalcemia and pancreatitis.

## DISCUSSION

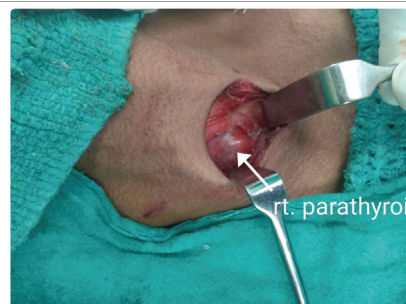
Cysts of the parathyroid gland are traditionally classified as either non-functional or as functional [3]. The majority of parathyroid cysts are non-functional, generally discovered during thyroid or cervical investigations, and are not associated with primary hyperparathyroidism. By contrast, functional cysts induce symptoms and signs of primary hyperparathyroidism. Their fluid contains high concentrations of Parathyroid Hormone (PTH), which may induce parathyroid crisis in case of rupture [3,4].

The incidence of parathyroid cysts in the general population is not known precisely. It was very low in a large series of consecutive neck USG (0.075%) and a prevalence of 3% was found in patients operated for cervical mass or hyperparathyroidism [5]. Moreover, a few series have reported on the incidence of functional cysts, which may vary from 10 to 33%. In a cohort of 1700 patients who had undergone surgery for primary hyperparathyroidism, six cases (<1%) of cystic transformation of the parathyroid glands were described, of which five were functional [4,6].


Proposed investigation and treatment algorithm in case of suspected parathyroid cyst (Figure 2).

## CONCLUSION

Symptomatic parathyroid cyst is a rare entity. Hypercalcemic crisis with features of acute pancreatitis in parathyroid cyst is also rare. Alcohol and gall stones are the two leading cause of acute pancreatitis [2,7]. Hypercalcemia is one of the rare cause of acute pancreatitis [8]. Aggressive and appropriate medical and surgical management is required in these cases. In this case surgical management of parathyroid cyst was done after proper initial conservative management of patient and he relieved from the sign and symptoms of acute pancreatitis. Further research paper and article require to establish the management of such rare cases.



**Figure 1:** Intraoperative picture of right parathyroid cyst which was later aspirated and excised.



## METHODS

I declare that consent has been obtained from patient or subject after full explanation of the purpose and nature of all procedures used. I also declare that approval is not required in our study as patient is not harmed during all procedure.

## DECLARATION OF INTEREST

The authors declare that there is no conflict of interest that could be perceived as prejudicing the impartiality of this review.

## FUNDING

This work did not receive any specific grant from any funding agency in the public, commercial, or not-for-profit sector.

## REFERENCES

- Cappelli C, Rotondi M, Pirola I, De Martino E, Leporati P, Magri F, et al. Prevalence of parathyroid cysts by neck ultrasound scan in unselected patients. *J Endocrinol Invest.* 2009; 32: 357-359. <https://goo.gl/x1wfA8>
- Delbridge LW, Younes NA, Guinea AI, Reeve TS, Clifton-Bligh P, Robinson BG. Surgery for primary hyperparathyroidism 1962-1996: indications and outcomes. *Med J Aust.* 1998; 168: 153-156. <https://goo.gl/h6UyaZ>
- Dutta D, Selvan C, Kumar M, Datta S, Das RN, Ghosh S, et al. Needle aspirate PTH in diagnosis of primary hyperparathyroidism due to intrathyroidal parathyroid cyst. *Endocrinol Diabetes Metab Case Rep.* 2013. <https://goo.gl/mFLX1H>
- Entwistle J, Pierce C, Johnson D, O'Donovan S, Bagwell C, Salzberg A. Parathyroid cysts: report of the sixth and youngest pediatric case. *J Pediatr Surg.* 1994; 29: 1528-1529. <https://goo.gl/yhSnoM>
- Goomany A, Rafferty A, Smith I. An unusual neck mass: a case of a parathyroid cyst and review of the literature. *Case Rep Surg.* 2015. <https://goo.gl/RgXvqz>
- Lassaletta L, Bernáldez R, García-Pallarés M, Morera E. Surgical management of recurrent parathyroid cyst. *Auris Nasus Larynx.* 2002; 29: 83-85. <https://goo.gl/vPYWvQ>
- Pacini F, Antonelli A, Lari R, Gasperini L, Baschieri L, Pinchera A. Unsuspected parathyroid cysts diagnosed by measurement of thyroglobulin and parathyroid hormone concentrations in fluid aspirates. *Ann Intern Med.* 1985; 102: 793-794. <https://goo.gl/bRprEV>
- Sung J, Baek J, Kim K, Lee D, Ha E, Lee J. Symptomatic nonfunctioning parathyroid cysts: role of simple aspiration and ethanol ablation. *Eur J Radiol.* 2013; 82: 316-320. <https://goo.gl/8Bqv85>