



International Journal of Reproductive Medicine & Gynecology

Research Article

Delayed Hysteroscopic Removal of Retained Products of Conception is Associated with Spontaneous Expulsion -

Jordina Munros¹, Meritxell Gracia^{1*}, Roser Nonell¹, Montserrat Cardona¹, Purificacion Lavilla¹, Arantxa Garcia², Juan Balasch¹, Francisco Carmona¹

¹Department of Gynecology, Institute Clinic of Gynecology, Obstetrics and Neonatology, Hospital Clinic, Institute of Biomedical Research August Pi i Sunyer (IDIBAPS), Faculty of Medicine-University of Barcelona, Barcelona, Spain .

²Surgical Area, Hospital Clinic, Faculty of Medicine-University of Barcelona, Barcelona, Spain.

***Address for Correspondence:** Meritxell Gracia, Department of Gynecology, Institute Clinic of Gynecology, Obstetrics and Neonatology, Hospital Clinic, Institute of Biomedical Research August Pi i Sunyer (IDIBAPS), Faculty of Medicine-University of Barcelona, Villarroel, 170, 08036 Barcelona, Spain. Tel: +0034-2275436; Fax: +0034-2279325; E-mail: megracia@clinic.cat; megracia@clinic.ub.es

Submitted: 03 May 2017; **Approved:** 29 May 2017; **Published:** 31 May 2017

Citation this article: Munros J, Gracia M, Nonell R, Cardona M, Lavilla P, et al. Delayed Hysteroscopic Removal of Retained Products of Conception is Associated with Spontaneous Expulsion. SRL Reprod Med Gynecol. 2017;3(1): 024-028.

Copyright: © 2017 Gracia M, et al. This is an open access article distributed under the Creative Commons Attribution License, which permits unrestricted use, distribution, and reproduction in any medium, provided the original work is properly cited.



ABSTRACT

Retained Products of Conception (RPOC) occur in 1 % of cases. Clinical features of 41 women diagnosed of RPOC by hysteroscopy, to establish the best time-lapse of an expectant management after an office hysteroscopy avoiding an operative hysteroscopy to permit a spontaneous expulsion, were analyzed. There were no differences between patients who suffered a spontaneous expulsion or those in whom a persistence of RPOC was observed at time of surgical removal in terms of age, gravidity, prior uterine surgeries, uterine alterations, type and time of pregnancy termination and ultrasonographic characteristics. There was a higher rate of spontaneous expulsion after 4 weeks from the office hysteroscopy compared with those where the surgical removal was performed up to 4 weeks after the diagnosis (*p-value* 0.011).

It might be possible a 4-week delay of the RPOC removal after having performed an office hysteroscopy in order to let the possibility of a spontaneous expulsion.

Keywords: Retained products of conception; Office hysteroscopy; Operative hysteroscopy; Ultrasonography; Spontaneous expulsion; Termination of pregnancy

INTRODUCTION

Retained Products of Conception (RPOC) are not an unusual outcome after miscarriage, Termination of Pregnancy (TOP) and vaginal or caesarean delivery. It is estimated to occur in approximately 1% of cases, although it could be higher in cases of TOP depending on the treatment regimen [1].

The presence of RPOC can be diagnosed due to short-term clinical manifestations such as abnormal uterine bleeding, abdominal pain, fever, dilated cervical canal or secondary amenorrhea; and it can lead to long-term consequences such as infertility, Intrauterine Adhesions (IUA) formation or repeated spontaneous miscarriages. RPOC are suspected in a transvaginal Doppler Ultrasonography when intracavitary homogeneous or heterogeneous echogenic foci or endometrial fluid collection with echogenic foci are detected, as well as the finding of high-velocity, low-resistance flow at colour Doppler Ultrasonography [2-4].

In terms of management, it has been described an expectant management and also the use of treatments such as ergotamine or misoprostol, but RPOC are mainly managed surgically by Dilatation and Evacuation (D&E) or by hysteroscopic removal [1,5]. Several studies have reported the comparison between the use of D&E and hysteroscopy referring to post-operative IUA formation, surgical complications, rate of incomplete removal and pregnancy outcomes, as well as the safety and effectiveness of hysteroscopic removal, and it seems that the latter would be superior compared with D&E [6-8]. Nevertheless, there is a paucity of studies regarding the best time to perform the hysteroscopic removal of RPOC after the end of the pregnancy in order to permit a possible spontaneous expulsion, thus avoiding complications such as fluid overload, formation of IUA, uterine bleeding, infection or uterine perforation, as well as those related to the anaesthesia.

The aim of this study was to analyse the clinical features of patients affected of RPOC and to establish if a 4-week expectant management after an office hysteroscopy would permit the chance of a spontaneous expulsion before performing an operative hysteroscopy, thus avoiding possible complications related to surgical procedures during the removal.

MATERIALS AND METHODS

From July 2009 to June 2015 all patients diagnosed of RPOC by an office hysteroscopy performed in the Hysteroscopic Unit of Hospital

Clinic of Barcelona with a histopathologic study confirmation were included in this study. They were sent to our unit in case of suspicion of RPOC beyond one month of the end of pregnancy and in absence of acute symptoms (defined as heavy uterine bleeding, heavy abdominal pain or fever), in which cases a D&E was preferred. The present study was approved by the Ethics Committee from our institution and an informed consent was obtained from all patients.

After the diagnostic of RPOC an operative hysteroscopy was indicated. The possibility of a spontaneous expulsion during the waiting list was explained to the patients and if they accepted, the surgical procedure was scheduled as a non-high-priority surgery. All patients underwent preoperative complete blood sample test with blood cell count and coagulation test. Patients affected of RPOC were instructed to ask to our unit in case of uterine bleeding, abdominal pain or fever before the surgical procedure. In the first case, patients underwent a transvaginal Ultrasonography in order to assess the persistence or the spontaneous expulsion of RPOC, in which case, a second-look office hysteroscopy was performed to confirm uterine vacuity. In case of abdominal pain or fever a D&E under antibiotic treatment was preferred.

Hysteroscopic transcervical removal of RPOC was performed under general anaesthesia and antibiotic prophylaxis was administered to all of them. A 26Fr resectoscope (Karl Storz, Tuttlingen, Germany) assembled to a 4-mm cutting loop was introduced into the uterine cavity after mechanical cervical dilation with Hegar's dilators to no. 10. No prostaglandins were used for cervical ripening. The uterine cavity was distended and irrigated by saline solution and bipolar energy was used, controlled by an electronic device (Hysteroflator; Karl Storz, Tuttlingen, Germany) and fluid balance was recorded. The loop was used mechanically as a curette, avoiding the use of electrosurgery, which was applied only if necessary due to bleeding or difficulties in the removal procedure. Tissue obtained was sent for histopathologic study. Surgery duration, intraoperative and postoperative complications were recorded. All procedures were performed by the same medical team.

The following variables were recorded: age, gravidity, prior uterine surgeries (defined as prior D&E, C-section, operative hysteroscopy or myomectomy), presence of uterine alterations such as leiomyomas and malformations, history of placental retention in the last end of pregnancy (including incomplete miscarriages, postpartum D&E or manual revision of uterus after delivery), time of pregnancy



termination (first or second trimester, preterm and term delivery) and type of termination (whether it was a spontaneous miscarriage, or it was managed by medical treatment with misoprostol or D&E, or in case of preterm and term deliveries, whether they were vaginal deliveries or C-section), endometrial thickness and characteristics of colour Doppler flow at ultrasonographic study performed due to RPOC suspicion. Rate differences between spontaneous expulsion and persistence of RPOC at operative hysteroscopy up to 4 weeks and after 4 weeks from the office hysteroscopy were assessed.

Continuous variables were compared using a nonparametric Mann-Whitney U test and categorical variables were compared using Chi-square or Fisher exact test, if appropriate. The SPSS version 20.0 software (IBM, Armonk, NY, USA) was used for the statistical analysis. *p-value* < 0.05 was considered statistically significant.

RESULTS

Forty-one patients were diagnosed of RPOC by an office hysteroscopy and a histopathologic study confirmation. The suspicion of RPOC before the hysteroscopy was reached either by performing a transvaginal Ultrasonography, with colour Doppler study if feasible, due to clinical complaints such as vaginal bleeding after the end of the last pregnancy (miscarriage, TOP, vaginal delivery or C-section), amenorrhea, abdominal pain or during the follow-up after a miscarriage or TOP. One patient required D&E under endovenous antibiotic therapy due to fever after the performance of an office hysteroscopy. Five patients presented uterine bleeding after the office hysteroscopy while waiting for the surgical procedure, a transvaginal ultrasonography was performed and no signs of RPOC were observed. These patients underwent a second-look office hysteroscopy, which confirmed uterine vacuity. None of the patients presented heavy abdominal pain before the surgery.

Finally, 35 patients underwent an operative hysteroscopy for the removal of RPOC. In six patients no intrauterine findings were found, so a spontaneous expulsion was assumed. After explaining to these patients the absence of findings, all of them referred a single episode of spontaneous bleeding while waiting for the operative hysteroscopy, not having referred it before the procedure. A hysteroscopic removal was then performed in 29 patients. Only three patients suffered surgical complications during the procedure: 1 cervical laceration, 2 heavy uterine bleedings that were solved with intramuscular injection of ergometrine and intrauterine balloon with Foley catheter during 12 hours. No other complications were registered before, during or after the procedure. Figure 1 shows the flow of events described above.

Baseline characteristics of the 40 patients affected by RPOC (1 patient out of the 41 underwent a D&E due to fever) either if they underwent hysteroscopic removal or they suffered a spontaneous expulsion are shown in Table 1. There were no differences in any of the variables shown, when compared between women with persistence of RPOC at the time of operative hysteroscopy and those in whom uterine vacuity was observed, except for the time lapse from the office hysteroscopy to the surgical procedure (figure 2 shows time lapse differences in weeks between patients who suffered a spontaneous expulsion and those in whom a persistence of RPOC was observed in the operative hysteroscopy). There was a higher rate of spontaneous expulsion after 4 weeks from the office hysteroscopy (90.9 %) compared with the group of patients where the surgical removal was performed up to 4 weeks after the diagnosis (*p-value* 0.011).

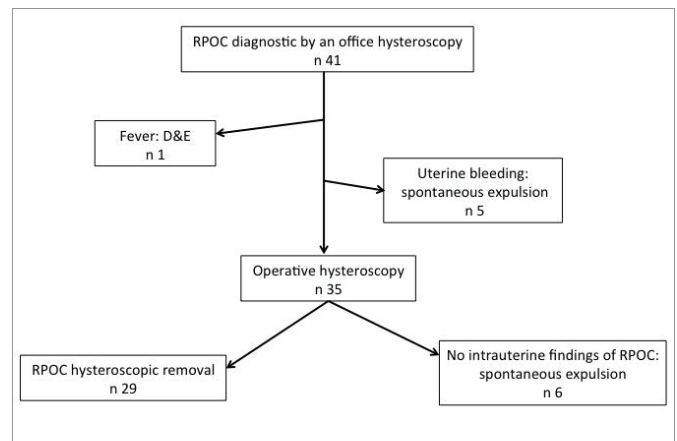


Figure 1: Flow of events of patients with a diagnostic of RPOC by an office hysteroscopy. RPOC: Retained Products of Conception, D&E: Dilatation and Evacuation.

Table 1: Differences between cases with removal of RPOC (n = 29) and cases with spontaneous expulsion (n = 11) in the 40 patients affected by RPOC.

	Hysteroscopic removal of RPOC (n = 29)	Spontaneous expulsion (n = 11)	<i>p-value</i>
Type of pregnancy termination			0.298
First trimester - spontaneous	6 (20.7%)	1 (9.1%)	
First trimester – medical treatment	1 (3.4%)	2 (18.2%)	
First trimester – D&E	5 (17.2%)	3 (27.3%)	
Second trimester – spontaneous	1 (3.4%)	1 (9.1%)	
Second trimester – medical treatment	3 (10.3%)	3 (27.3%)	
Preterm vaginal delivery	2 (6.9%)	0	
Preterm caesarean-section	0	0	
Term vaginal delivery	9 (31%)	1 (9.1%)	
Term caesarean-section	2 (6.9%)	0	
Age (years)	36 (30-41, 34-37)	36 (25-42, 31-38)	0.881
Primigravida	11 (37.9%)	3 (27.3%)	0.404
Uterine surgery	10 (34.5%)	4 (36.4%)	0.596
Uterine alteration ^a	2 (6.9%)	1 (9.1%)	0.630
Placental retention	11 (37.9%)	4 (36.4%)	0.613
Endometrial thickness (mm)	21 (4-64, 16-28)	16 (10-38, 13-26)	0.321
Characteristical flow at colour Doppler ultrasonography	18 (78.3%)	5 (83.3%)	0.430

Continuous variables are expressed in median (range, 25th-75th percentiles) and were compared using a nonparametric Mann-Whitney U test. Categorical variables were compared using Chi-square or Fisher exact test, if appropriate. ^aCases of uterine alterations were a type 2 leiomyomata and an arquate uterus in case of persistence of RPOC and a type 2 leiomyomata in case of spontaneous expulsion. RPOC: Retained Products of Conception; D&E: Dilatation and Evacuation.

DISCUSSION

Retained products of conception are a complication described after miscarriage, TOP or deliveries that have been traditionally treated by D&E. Nevertheless, in the last few years, several studies have reported the benefits of performing a hysteroscopic selective curettage instead of D&E [7,8]. Operative hysteroscopy with a selective curettage limited to the area affected by RPOC performed with direct vision could avoid the rest of healthy endometrial surface from suffering a blind curettage that could lead to inflammation, scar formation and finally Intrauterine Adhesions (IUA) or Asherman’s syndrome development [6]. Moreover, it permits the assessment of the

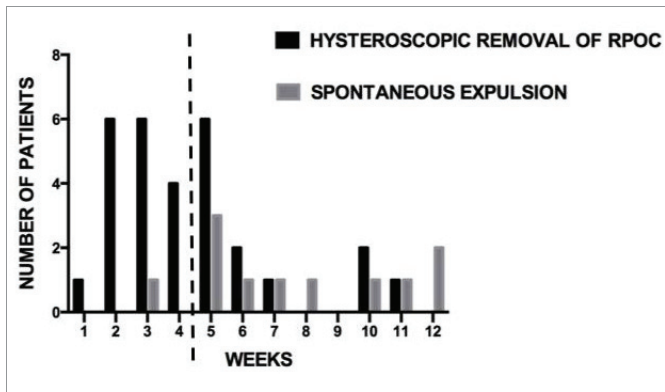


Figure 2: Time lapse (weeks) between office and operative hysteroscopy or diagnostic of spontaneous expulsion in case of patients with spontaneous expulsion and patients who underwent a hysteroscopic removal of RPOC (Retained Products of Conception).

complete removal of RPOC without the need of a second procedure, which is not uncommon in cases where a D&E is performed. The surgical technique using the loop of the resectoscope as a curette limiting the use of electrosurgery would reduce thermal damage to the endometrium, adding the chance of treating uterine cavity anomalies if present [7]. Apart from this, it has been hypothesised that continuous flushing of the uterus with sterile solution during the hysteroscopy may reduce the risk of local infection and inflammation processes that could contribute to adhesion formation [5]. When hysteroscopic removal is performed, it has been described less incidence of IUA detected by a second-look hysteroscopy and a tendency to earlier conception [8], although whether there is a higher conception rate remains unclear [5,6]. Operative hysteroscopy in such cases has been described as a simple, safe and efficient procedure [2], as well as relatively easy to learn and to perform [6].

Accordingly to the literature, taking into account the benefits of a hysteroscopic treatment of RPOC, if there is a paucity of symptoms, it would be better to postpone the hysteroscopy at least 1 month after the end of any type of pregnancy, due to the technical difficulty if performed before, because of the uterus enlargement and cervical dilation, thus increasing the risk of uterine perforation and leading to a larger spillage of distension medium, and also due to the higher risk of infection [6,9]. For this reason, D&E would be the method of choice for RPOC treatment during the first month, in cases of acute symptoms such as heavy uterine bleeding, heavy uterine pain, fever, or suspicion of other pathologies (for example, hydatidiform mole).

Although it seems that the hysteroscopic treatment would be the best treatment of choice for patients affected by RPOC [7], when the symptoms related to it are not acute, there is a lack of evidence regarding the best time to perform the removal of RPOC in order to permit the chance of a spontaneous expulsion, thus avoiding complications such as fluid overload, formation of IUA, uterine bleeding, infection or uterine perforation, as well as those related to anaesthesia. For this reason, the purpose of our study was to analyse whether it could be feasible an expectant management of RPOC after its diagnosis by an office hysteroscopy in order to let a spontaneous expulsion happen.

It has been compared the role of ultrasonography and hysteroscopy in the diagnostic of RPOC, showing the former a sensitivity of 86.3%, a specificity of 89.2% and positive predictive value of 67.9%, and the latter 77.2%, 92.8% and 73.9%, respectively, with only a significant

difference in sensitivity, suggesting the use of hysteroscopy only as an operative tool [10]. Nevertheless, in our opinion, after having assessed the uterine cavity with a transvaginal ultrasonography to all patients with RPOC suspicion, it would be recommendable to perform an office hysteroscopy as a diagnostic tool before scheduling the removal of RPOC in an operating room since it is a safe outpatient procedure (in our study we only reported one complication: a patient who underwent fever few days after the procedure), nearly painless and with a diagnostic accuracy similar to the ultrasonography, adding some benefits to the patient such as the possibility of a biopsy in case of diagnostic doubts or suspicion of other pathologies, and the possible reduction of risk of infection and intrauterine adhesions formation because of the irrigation. In addition, we hypothesise its contribution to the spontaneous expulsion of the RPOC due to the cervical dilation and the irrigation of the intrauterine cavity, without affecting the endometrial surface. For this reason, we do not consider a “see and treat” hysteroscopy in cases of RPOC.

All these factors described would undoubtedly contribute to the reduction of unnecessary surgical procedures according to our data: from 40 cases where an operative hysteroscopy was scheduled, 27.5% of them (n = 11) suffered a spontaneous expulsion before the surgical procedure. We analysed several variables to determine if some showed a relation with a spontaneous expulsion in order to predict which patients would benefit of an expectant management and only the time lapse from the office hysteroscopy to the hysteroscopic removal of RPOC or the diagnosis of spontaneous expulsion showed a statistically significant difference, being longer in cases where a uterine vacuity was observed compared with persistence of RPOC.

Therefore, in cases of RPOC suspicion we suggest, according to our data, to assess the uterine cavity with an ultrasonography and also an office hysteroscopy to confirm the diagnosis always after 1 month of the end of pregnancy. If there are no acute symptoms and patient accepts an expectant management, a new assessment of the uterine cavity would be performed after 4 weeks or before in cases of heavy uterine bleeding. If indicated because of the persistence of RPOC, a hysteroscopic removal should then be performed.

CONCLUSION

In conclusion, although this is a study with a reduced sample size due to the low incidence of this pathology, it is the first to our knowledge where the optimal time to perform the removal of RPOC in women without acute symptoms is assessed. Our data suggest that it might be possible a 4-week delay of the RPOC removal after having performed an office hysteroscopy in order to let the possibility of a spontaneous expulsion, thus avoiding complications related to the surgical and anaesthetic procedures, without increasing the risk of infection. Further prospective studies with larger sample sizes are necessary in order to assess the absence of complications after an office hysteroscopy in cases of RPOC suspicion and also to evaluate the outcomes of offering an expectant management when possible in terms of spontaneous expulsion rates, possible intrauterine infections and intrauterine adhesions formation.

IMPACT STATEMENT

What is already known on this subject: Several studies report that hysteroscopic removal seems better than dilatation and evacuation, but the best time to perform it in order to permit a possible spontaneous expulsion has not been established.



What the results of this study add: In cases of RPOC suspicion we suggest, to assess the uterine cavity with an ultrasonography and also an office hysteroscopy to confirm the diagnosis always after 1 month of the end of pregnancy. If there are no acute symptoms and patient accepts an expectant management, a new assessment of the uterine cavity would be performed after 4 weeks. If indicated because of the persistence of RPOC, a hysteroscopic removal should then be performed.

What the implications are of these findings for clinical practice and/or further research: It could be feasible an expectant management of RPOC after its diagnosis by an office hysteroscopy in order to let a spontaneous expulsion happen, thus avoiding complications such as fluid overload, formation of intra uterine adhesions, uterine bleeding, infection or uterine perforation, as well as those related to anaesthesia.

REFERENCES

1. Russo JA, DePiñeres T, Gil L. Controversies in family planning: retained products of conception. *Contraception*. 2012; 86: 438-442. <https://goo.gl/Lpv8s3>
2. Faivre E, Deffieux X, Mrazguia C, Gervaise A, Chauveaud-Lambling A, Frydman R, et al. Hysteroscopic management of residual trophoblastic tissue and reproductive outcome: a pilot study. *J Minim Invasive Gynecol*. 2009; 16: 487-490. <https://goo.gl/iVOiR9>
3. Sellmyer MA, Desser TS, Maturen KE, Jeffrey RB Jr, Kamaya A. Physiologic, histologic, and imaging features of retained products of conception. *Radiographics*. 2013; 33: 781-796. <https://goo.gl/y83ZO5>
4. Matijevic R, Knezevic M, Grgic O, Zlodi-Hrsak L. Diagnostic accuracy of sonographic and clinical parameters in the prediction of retained products of conception. *J Ultrasound Med*. 2009; 28: 295-299. <https://goo.gl/HkR6cQ>
5. Rein DT, Schmidt T, Hess AP, Volkmer A, Schondorf T, Breidenbach M. Hysteroscopic management of residual trophoblastic tissue is superior to ultrasound-guided curettage. *J Minim Invasive Gynecol*. 2011; 18: 774-778. <https://goo.gl/kcYRKH>
6. Cohen SB, Kalter-Ferber A, Weisz BS, Zalel Y, Seidman DS, Mashiach S, et al. Hysteroscopy may be the method of choice for management of residual trophoblastic tissue. *J Am Assoc Gynecol Laparosc*. 2001; 8: 199-202. <https://goo.gl/vHXmzl>
7. Smorgick N, Bareil O, Fuchs N, Ben-Ami I, Pansky M, Vaknin Z. Hysteroscopic management of retained products of conception: meta-analysis and literature review. *Eur J Obstet Gynecol Reprod Biol*. 2014; 173: 19-22. <https://goo.gl/4xPOzn>
8. Hooker AB, Aydin H, Brolmann HA, Huirne JA. Long-term complications and reproductive outcome after the management of retained products of conception: a systematic review. *Fertil Steril*. 2016; 105: 156-164. <https://goo.gl/ropfyz>
9. Golan A, Dishi M, Shalev A, Keidar R, Ginath S, Sagiv R. Operative hysteroscopy to remove retained products of conception: novel treatment of an old problem. *J Minim Invasive Gynecol*. 2011; 18: 100-103. <https://goo.gl/oDS5o1>
10. Vitner D, Filmer S, Goldstein I, Khatib N, Weiner Z. A comparison between ultrasonography and hysteroscopy in the diagnosis of uterine pathology. *Eur J Obstet Gynecol Reprod Biol*. 2013; 171: 143-145. <https://goo.gl/rfxSoF>