



International Journal of Neurological Disorders

Case Report

Activation Profile of Pectoralis Major, Deltoid and Supraspinatus Muscle in Brachial Plexus Injury Patient with Shoulder Subluxation using Shoulder Sling - a Case Report -

Poly Ghosh^{1*}, PK Lenka² and Abhishek Biswas³

¹M.sc (Prosthetics & Orthotics), National Institute for Locomotor Disabilities (Divyangjan)

²Head of the Department (Prosthetics & Orthotics), National Institute for Locomotor Disabilities (Divyangjan)

³Department of Physical Medicine & Rehabilitation, Director (NILD), National Institute for Locomotor Disabilities (Divyangjan)

***Address for Correspondence:** Poly Ghosh, M.sc (Prosthetics & Orthotics), National Institute for Locomotor Disabilities (Divyangjan), India, Tel: +91-7602-857320; E-mail: ghoshpoly19@yahoo.com; ghoshpoly35@gmail.com

Submitted: 19 March 2018; Approved: 16 May 2018; Published: 18 May 2018

Cite this article: Ghosh P, Lenka PK, Biswas A, Activation Profile of Pectoralis Major, Deltoid and Supraspinatus Muscle in Brachial Plexus Injury Patient with Shoulder Subluxation using Shoulder Sling - a Case Report. Int J Neurol Dis. 2018;2(1): 006-009.

Copyright: © 2018 Ghosh P, et al. This is an open access article distributed under the Creative Commons Attribution License, which permits unrestricted use, distribution, and reproduction in any medium, provided the original work is properly cited.

INTRODUCTION

Brachial plexus lesions frequently lead to significant physical disability, psychological distress, and socioeconomic hardship. Adult brachial plexus injuries can be caused by various mechanisms, including penetrating injuries, falls, and motor vehicle trauma. Often the diagnosis is delayed or ignored as the practitioner waits for some recovery. Expedient diagnosis and testing is the best means of maximizing functional return. Evaluators must remember that muscles will begin to undergo atrophy and lose motor end plates as soon as the proximal injury occurs [1]. The vast majority of brachial plexus injuries involve denervation of the shoulder's supporting musculature. A weak shoulder girdle allows subluxation of the glenohumeral joint. The shoulder joint is inherently unstable, although the capsule and ligaments play a supporting role in joint stability, the majority of support is provided through active contraction of the supraspinatus muscle. Therefore, significant weakening of the supraspinatus leads to shoulder subluxation [2]. However, Electromyography (EMG) study is required for muscle weakness by nerve damage. The study of muscle function through EMG is an established method for quantifying muscle activity through electrical activity [3]. In brachial plexus injury as nerve damaged occurred so electromyography is the best option to assess the muscle function [4]. Inappropriate muscle activation has been observed to contribute to shoulder instability and studies have reported that muscles can have both a stabilizing and destabilizing role [3]. Shoulder orthoses can be used to counteract the shoulder subluxation [2]. In BPI, shoulder subluxation is caused by supraspinatus muscle but whether any other muscle is involved to assess that EMG study is required. Studies suggested that in immobilized shoulder, some amount of EMG activity is present. In shoulder orthosis all of the shoulder muscles are immobilized. So, aim of this case report is to find out the patterns of shoulder muscle activity (deltoid, supraspinatus and pectoralis minor) in shoulder subluxation patient before and after using shoulder sling.

METHODOLOGY

Case report

A 40 years male brachial plexus injured patient reported to Department of Prosthetics and orthotics, National institute for Locomotor Disabilities, Kolkata, with chief complaint of shoulder subluxation and unable to use his left upper limb for activities of daily living. On observation, patient was having shoulder subluxation.

History

1 year before patients got injured as someone pull his left upper limb to help him to climb stairs and he felt sudden pain on shoulder joint. After sometimes he felt numbness in his left upper limb, he was immediately taken to local hospital and doctor diagnosed him as a brachial plexus injury, from then he was undergone treatment. Presently he came to our institute for further treatment.

On, examination:

- Shoulder subluxation = 3cm (Figure 1)
- Antero-inferior shoulder subluxation
- Elbow flexors power good to normal
- Hand and wrist muscle (flexors) power are good to normal
- Atrophy of deltoid and rotator cuff muscle

- Loss of Shoulder abduction, flexion, rotation and extension
- **Active shoulder elevation possible.**
- **Upper trunk and C5- C6 injury**

After Assessment, patient was prescribed standard shoulder sling. After using of shoulder sling for 1 week, shoulder muscle activation profile using EMG was taken with and without shoulder sling.

METHODS OF MEASURING SHOULDER GIRDLE MUSCLE ACTIVATION

Muscle activity was recorded by Ad instrument power lab EMG analyzer (Figure 3) using Surface electrode (AgCl). Data were recorded for 2 minutes and data analysed for middle 1 minute as first 30 seconds and last 30 seconds counted as noise.

Data was taken in four condition:

- Shoulder joint in resting condition (without sling support)
- Actively elevated shoulder position (without sling support)
- Shoulder joint in Resting condition (with sling support)
- Actively elevated shoulder position (with sling support)

Protocol of data collection: During data collection, the Patients were asked to sit on a chair in a relaxed condition.

SEMG (SURFACE ELECTROMYOGRAPHY) PRE-RECORDING PROCEDURE

Choice of electrode

Round shaped Silver/Silver Chloride (Ag/AgCl) surface electrode

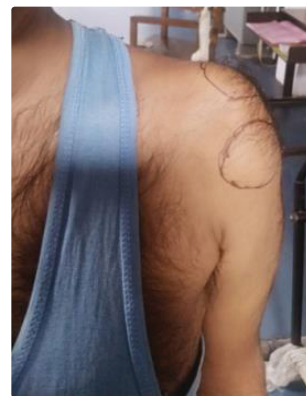

Figure 1: Showing shoulder subluxation .

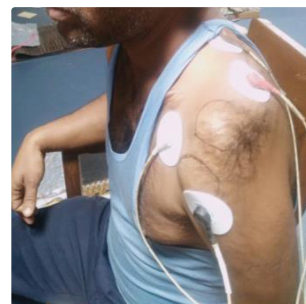


Figure 2: Placement of electrode SEMG Data recording procedure.



was used to record the EMG and attached with doubled adhesive tape to the patient. Conductive electrode gel was required to increase conductivity of the EMG signal.

Preparation of skin

To lower the skin resistance, the skin preparation including washing, wiping was done to have better EMG recordings. After the preparation of skin, surface electrode was placed in the forearm muscle belly and parallel to the muscle fiber, so that the maximum signal can be collected. AgCl gel was then applied to the reduce skin impedance.

Electrode placement

After scrubbing the area and properly cleaning the skin with alcohol, the surface electrode was placed lengthwise over the location of pectoralis minor, deltoid and supraspinatus. Electrodes location was determined using palpation while the subjects were alternatively activating and relaxing their muscles. Electrodes were placed on the thickest part of the muscle belly (Figure 2). Electrode must have good contact with the skin and must be aligned along the general direction of muscle fibers. The earth electrode was placed on the forearm.

One ground electrode:

Channel 3- black placed over deltoid anterior fibre & white placed pectoralis minor muscle

Channel 4- Red & brown-placed over supraspinatus

EMG signal data while simultaneously displaying up to 3 separate channels of EMG Signals to a standard computer screen for visual inspection. RMS amplitude was used to describe signal strength of SEMG signals.

RESULTS

Parameters	Shoulder joint in resting Position (without sling)		Actively elevated shoulder position (without sling)	
	Ch3	Ch4	Ch3	Ch4
Mean ± SD	-.0247 ± .08	.0206 ± .06	-.0295 ± .3	.0037 ± .34
Max. Value	0.6219	0.1675	4.1769	2.4325
Min. Value	-0.9081	-0.4475	-3.0144	-2.4413
RMS	0.8036	0.064	0.303	0.3371

Ch3 = Pectoralis & deltoid muscle group

Ch4 = supraspinatus muscle, unit of measurement = mV

DISCUSSION

A sling or other method of support is needed for patients with injuries to the brachial plexus nerves that control the shoulder and arm muscles. Damage to these Nerves can result in Partial or total loss of motor function of the arm and subluxation of the humeral head from the shoulder socket. Brachial plexus patients must rely on shoulder and arm supporting splints to fix this subluxation.




Figure 2: Computer screen with AD Instrument power lab.

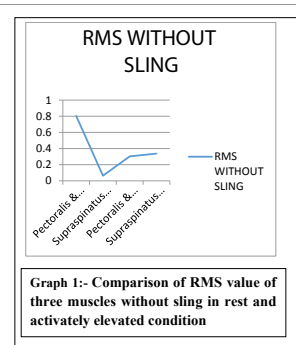
Result of the current study showed that in resting position without any sling support (Table 1), Pectoralis and Deltoid muscle (0.8036 mV) are more active and more stronger than Supraspinatus (0.064 mV), Supraspinatus is also active but that is negligible. During active elevation (Table 2) Supraspinatus muscle (.3371 mV) is stronger than Pectoralis and Delotid muscle (0.303 mV) but very less in comparison. But with sling support, in resting condition all the muscles (0.0637 & 0.0889 mV) amplitude is less but in elevation with sling support all the muscles are equally active.

This study contradict the study of Basmajian and Bazant [5] and MacConaill and Basmajian [6] reported that all muscles of the shoulder complex are electrically silent in the relaxed, unloaded limb and even when the limb is tugged vigorously downward [5]. Another study by Smith j suggested that immobilized shoulder girdle muscles are relatively inactive. RMS value increased in Supraspinatus muscle with sling support in both conditions which suggest that sling has effects on Supraspinatus muscle which may be due to sling may provide resistance to muscle activation even if support condition.

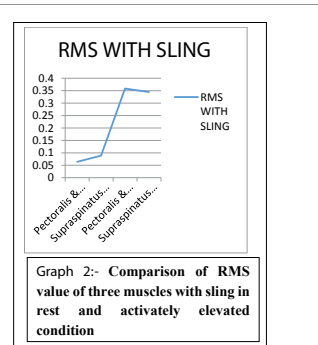
In this case patient was having brachial plexus injury, in spite of that muscles are showing some effects in EMG, that means

Table 1: RMS value of pectoralis major with Deltoid & Supraspinatus muscle without sling in rest and actively elevated position.

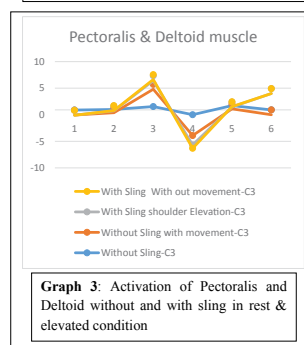
Parameters	Shoulder joint in Resting condition (with sling support)		Actively elevated shoulder position (with sling support)	
	Ch3	Ch4	Ch3	Ch4
Mean ± SD	-.03 ± .05	.024 ± .08	-.012 ± .35	.021 ± .34
Max. Value	0.2144	0.6075	1.6219	2.065
Min. Value	-0.6356	-0.54	-1.7656	-3.21
RMS	0.0637	0.0889	0.3587	0.3446



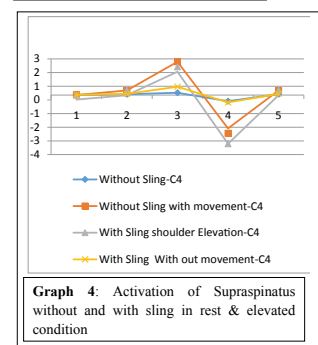
Graph 1:- Comparison of RMS value of three muscles without sling in rest and actively elevated condition



Graph 2:- Comparison of RMS value of three muscles with sling in rest and actively elevated condition



Graph 3: Activation of Pectoralis and Deltoid without and with sling in rest & elevated condition



Graph 4: Activation of Supraspinatus without and with sling in rest & elevated condition

Table 2: RMS value of pectoralis major with Deltoid & Supraspinatus muscle with sling in rest and actively elevated position.



muscles are not totally paralyzed but partially paralyzed and sling has some support effects. From this study it may be concluded that, use of shoulder sling play a vital role in the prevention of shoulder subluxation and help in muscle activity augmentation. Limitation of the study is the data is not compared with normal subjects and normal side.

ACKNOWLEDGEMENT

The authors sincerely acknowledged Dr. Abhishek Biswas, Director of National Institute for Locomotor Disabilities (Divyangjan) for allowing to use Gait lab.

REFERENCES

1. Moran SL, Steinmann SP, Shin AY. Adult brachial plexus injuries: mechanism, patterns of injury, and physical diagnosis. *Hand clinics*. 2005; 21: 13-24. <https://goo.gl/fpgCXo>
2. John D. Hsu, John W. Michael, John R. Fisk, AAOS Atlas of orthoses and assistive device. American academy of orthopaedic surgeons. Elsevier Health Sciences. 4th edition. 254. <https://goo.gl/zZwqmT>
3. Jaggi A, Noorani A, Malone A, Cowan J, Lambert S, Bayley I. Muscle activation patterns in patients with recurrent shoulder instability. *Int J Shoulder Surg*. 2012; 6: 101-107. <https://goo.gl/X4BpzA>
4. Raghig H, Young GB, Hammond R, Nicolle M. A comparison of EMG and muscle biopsy in ICU weakness. *Neurocritical care*. 2010; 13: 326-330. <https://goo.gl/5YEjQW>
5. Basmajian J, Bazant FJ. Factors preventing downward dislocation of the adducted shoulder joint. An electromyographic and morphological study. *J Bone Joint Surg Am*. 1959; 41-A: 1182-1186. <https://goo.gl/m5JiyQ>
6. M A MacConaill, John V Basmajian. *Muscles and movement: A basis for human kinesiology*. Baltimore, Williams & Wilkins. 1969. <https://goo.gl/3WTbVU>
7. Smith J, Padgett DJ, Dahm DL, Kaufman KR, Harrington SP, Morrow DA, et al. Electromyographic activity in the immobilized shoulder girdle musculature during contralateral upper limb movements. *J Shoulder Elbow Surg*. 2004; 13: 583-588. <https://goo.gl/SUZmhf>