



International Journal of Case Reports & Short Reviews

Case Report

Primary Amenorrhea after Sex-Mismatched Allogeneic Hematopoietic Stem Cell Transplantation: a Case Report and Literature Review - ②

Tianji Liao^{1,2#}, Li Xiao^{1,2}, Minjin Wang³, and Wei Huang^{1,2##}

¹Department of Obstetrics and Gynecology, West China Second University Hospital of Sichuan University, Chengdu, 610041, Sichuan, China

²Key Laboratory of Birth Defects and Related Diseases of Women and Children (Sichuan University), Ministry of Education, Chengdu, 610041, Sichuan, China

³Department of Laboratory Medicine, West China Hospital, Sichuan University, Chengdu, 610041, China

#Authors are contributed equally to this article

***Address for Correspondence:** Wei Huang, Department of Obstetrics and Gynecology, West China Second University Hospital of Sichuan University, 3 duan 20 hao Renminnanlu, Chengdu Sichuan 610041, China, Fax: +862-885-441-799; Tel: +861-388-185-8999; E-mail: weihuang64@163.com

Submitted: 24 August 2018; Approved: 27 September 2018; Published: 08 October 2018

Cite this article: Huang W, Liao T, Xiao L, Wang M. Primary Amenorrhea after Sex-Mismatched Allogeneic Hematopoietic Stem Cell Transplantation: a Case Report and Literature Review. Int J Case Rep Short Rev. 2018;4(3): 040-043.

Copyright: © 2018 Huang W, et al. This is an open access article distributed under the Creative Commons Attribution License, which permits unrestricted use, distribution, and reproduction in any medium, provided the original work is properly cited.



ABSTRACT

A female patient with primary amenorrhea and 46 XY karyotype can be commonly diagnosed as Y chromosome-related Disorders of Sex Development (DSD) by physicians, which may be not always a correct diagnosis. An 18-year-old girl was evaluated for her primary amenorrhea. Her karyotyping analysis revealed 46 XY. She was diagnosed as aplastic anemia and treated with sex-mismatched allogeneic hematopoietic stem cell transplantation donated from her father when she was ten years old. We finally detected this patient's personal identification was a female by her hair follicle samples, which indicated that DSD was an inappropriate diagnosis for her. Her menstruation presented regularly after we prescribed estrogen-progestin regimen for her. The aim of this case report was to improve the understanding of diagnosis, workup, and treatment of this special primary amenorrhea in the general gynecology practice.

Keywords: Primary amenorrhea; Allogeneic hematopoietic stem cell transplantation; Hair follicle; Primary ovarian insufficiency

INTRODUCTION

Primary amenorrhea is diagnosed by meeting 1 of 2 criteria: no period by the age of 14 years in the absence of growth or development of secondary sex characteristics, or no period by age 16 years regardless of the presence of normal growth and development with the appearance of secondary sex characteristics [1]. There are numerous etiologies including outflow tract obstructions, gonadal dysgenesis, and anomalies of the hypothalamic axis [2]. A female patient with primary amenorrhea and 46 XY karyotype can be commonly diagnosed as Y chromosome-related Disorders of Sex Development (DSD) by clinical physicians. However, it was not always a correct diagnosis. As hematopoietic and lymphoid cells of the patients will be replaced by cells derived from the donors' marrow after successful allogeneic Hematopoietic Stem Cell Transplantation (allo-HSCT), peripheral blood is not suitable for personal identification or kinship study in individuals who have a history of successful allo-HSCT [3]. Here we reported a unique case of an 18-year-old girl with primary amenorrhea and 46 XY karyotype after sex-mismatched allo-HSCT, finally detected her personal identification as a female by hair follicle samples and hormone treatment has been used to recover her menstruation.

CASE REPORT

An 18-year-old girl referred to our hospital for primary amenorrhea. Physical examination revealed a well-developed and nourished woman with normal intelligence, a height of 162cm, and a weight of 44kg, she had female genitalia with visible vaginal orifice, urethral orifice, and a normal size clitoris with scanty pubic and axillary hairs (Tanner stage II) and developed breasts (Tanner stage IV).

Laboratory examination showed a 46 XY Karyotype with significantly elevated Follicle Stimulating Hormone (FSH) (170.1 mIU/ml), elevated Luteinizing Hormone (LH) (57.4 mIU/ml), low estrogen (E2) (33 pg/ml), Prolactin (PRL) (14.24 ng/mL), Testosterone (T) (0.27 ng/ml), and Progesterone (P) (0.62 ng/mL). Anti-Mullerian Hormone (AMH) was low (< 0.06 ng/ml) and bone development delayed. The hormone level showed in table 1. Transabdominal ultrasound revealed a small uterus (anteroposterior diameter 2.6cm) and ovaries (left ovary:1.9*1.1*1.5cm right ovary:1.8*0.9*1.5cm). There was no history or clinical presence of an inguinal hernia. No family member had similar symptoms. She was diagnosed as aplastic anemia and treated with once chemotherapy and sex-mismatched allo-HSCT donated from her father at 10 years old. No sign of aplastic anemia recurrence has been shown until now.

Blood, buccal swabs with epithelial cells, as well as hair follicles, are among the most commonly investigated materials in forensic

Table 1: Hormone Level.

Hormone Level		Reference value
E2 (pg / ml)	33.0	27 - 122
P (ng / ml)	0.62	0.31 - 1.52
T (ng / ml)	0.27	0.1 - 0.75
LH (mIU / ml)	57.4	2.12 - 10.89
FSH (mIU / ml)	170.1	3.85 - 8.78
PRL(ng / ml)	14.24	3.34 - 26.72
AMH (ng / ml)	< 0.06	

genetic [4]. It is a well-documented fact that blood from who had a successful allo-HSCT is not suitable for personal identification and kinship analysis, because of its conversion to a complete donor type [5]. Therefore, we should confirm the patient forensic identification by other materials, as several approaches have been published for the detection of chimerism. In sex-mismatched transplantation settings, information on the ratio between donor and recipient can be obtained efficiently and rapidly by using fluorescent in situ-hybridization with probes specific for X- and Y-chromosome [6,7]. The Polymerase Chain Reaction (PCR) based amplification of a single Variable Number Of Tandem Repeat (VNTR) or Short Tandem Repeat (STR) markers is also frequently performed [6,8]. Zhou et al. [9] documented 100% of recipient's DNA profiles without detecting any donor-origin genetic material in hair from recipients of allo-HSCT, by applying autosomal STR-PCR analysis as their only investigatory method. However, Jacewicz et al. [10] proved the existence of donor-derived stem DNA in the recipients' hair follicle cells. With the opposite results, we analyzed the patient's and her parent's blood samples, and her hair follicle samples. The results were showed in table 2. PCR-based amplification of STR markers analysis showed her DNA profiles obtained from patient's blood samples were 100% matched with her father's type, Amel genes collected from her hair follicle sample showed XX which was partly different from her mother's that is accorded with Mendel's law. We can confirm this patient's innate karyotype was XX, she was not suffering from DSD. The explanation was showed in (Figure 1).

The changed karyotype after allo-HSCT well indicated that the patient's clinical features were not consistent with the typical 46 XY karyotype DSD. The reason of primary amenorrhea could be ovarian hypofunction associated with allo-HSCT. The sex hormone levels suggested poor ovarian function. Because of hormone deficiency, patients with primary amenorrhea are prone to osteoporosis and cardiovascular diseases. Continuous hormonal substitution is the key treatment. We prescribed estrogen-progestin regimen for her. Her menstruation presented regularly during treatment. The case

Table 2: Results of STR profiling: her fathers blood numbered 8888-1, her mother's numbered 8888-2, her blood sample numbered 8888-3, her hair follicle sample numbered 8888-5.

genetic loci	2017-03-8888-01	2017-03-8888-02	2017-03-8888-03	2017-03-8888-05
D19S433	14 16.2	14 14.2	14 16.2	14 16.2
D5S818	11 12	11 12	11 12	12
D21S11	29 30	29 30	29 30	29 30
D18S51	14 16	13 14	14 16	13 16
D6S1043	11 12	18 19	11 12	12 19
D3S1358	15 16	16 18	15 16	15 16
D13S317	11	8 10	11	10 11
D7S820	8 11	11 13	8 11	11
D16S539	11 12	9	11 12	9 12
CSF1PO	10 13	9 12	10 13	10 12
Penta D	9	9	9	9
vWA	14	17	14	14 17
D8S1179	12	15	12	12 15
TPOX	9 10	8 11	9 10	10 11
Penta E	11 12	11 18	11 12	12 18
TH01	8 9	9	8 9	8 9
D12S391	23 24	18 21	23 24	21 24
D2S1338	18	24	18	18 24
FGA	21 23	20 23	21 23	21 23
Amel	X Y	X X	X Y	X X

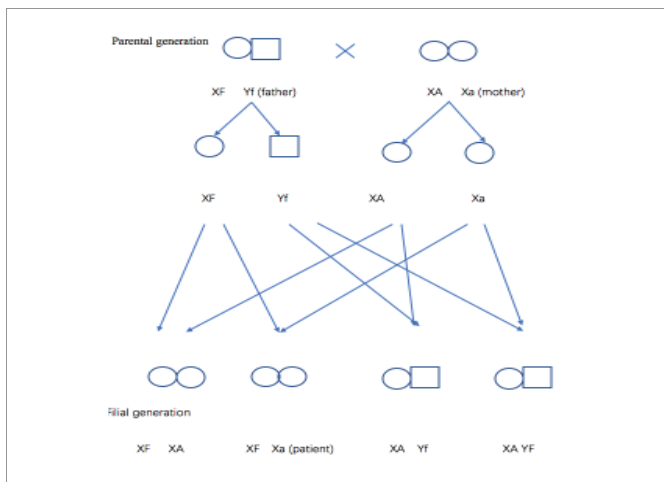


Figure 1: Mendel's law.

report was approved by the Institutional Review Board of West China Second University Hospital of Sichuan University. Informed consent was given by the patient and her parents.

DISCUSSION

In the past 3 decades, allo-HSCT has been extensively used to treat patients with malignant hematological diseases or nonmalignant hematological diseases, such as severe aplastic anemia, severe combined immunodeficiency and hemoglobinopathies. The patient was cured by allo-HSCT. But then she met another problem that there was no occurrence of menstruation when she grew up. As patients

with primary amenorrhea and chromosomal abnormalities who had been treated with sex-mismatched allo-HSCT might be misdiagnosed as DSD, collecting medical history and undergoing related gene analysis are important to identify DSD in clinical practice.

The allo-HSCT may cure patients with hematologic malignancies, but it carries significant risks. Stern et al. [11] investigated that female patients with male donors had a decreased survival and an increased risk of rejection compared to recipients of sex-matched grafts. Chemotherapy, particularly alkylating agents, is found to impose the highest risk of causing ovarian insufficiency, and there is a high risk of persistent Primary Ovarian Insufficiency (POI) in female patients who undergo allo-HSCT [12]. In 1995, a survey study of 38,000 male and female patients or their partners who received chemotherapy and radiation with allo-HSCT found that the fecundity rate was extremely low, with only 129 pregnancies reported [13]. More importantly, if POI left untreated, it would leave the patient with long-term health risks.

Huang and Tian [14] reported a case of an 18 years old girl with primary amenorrhea and 46XY karyotype after allo-HSCT and adjuvant chemotherapy. She received DAE (Ida+AraC+VP-16), improved Bu/Cy (AraC+busulfan+CTX+VM-26+MeCCNU), MTX+MD-AraC, CAG (AraC+ACR+G-CSF), and HAG (AraC+HHT+G-CSF) intravenous chemotherapy. The chemotherapy contained busulfan and Cyclophosphamide (CTX), which had been proved highly toxic to ovary and probably caused Primary Ovarian Insufficiency (POI). However this patient was different, as this patient suffered aplastic anemia when 10 years old without menarche or appearance of secondary sexual characteristics (according to the patient's memory). Though she underwent one regimen chemotherapy before allo-HSCT (concrete proposal was unknown), the ovary is hardly be damaged by chemotherapy agents during pre-puberty. To our knowledge, there is no evidence currently that sex-mismatched allo-HSCT alone also affect the gonadal function and pubertal development. The reason for her primary amenorrhea is unknown.

At the same time Huang and Tian [14] reviewed the whole medical record carefully, and demonstrated the patient personal identification by her bone marrow chromosome karyotype before allo-HSCT. Recently, bone marrow stem cells have been considered to have the potential to 'transdifferentiate' or 'dedifferentiate' into neural, bone, muscular, cartilage, liver, gut, alveolar, epidermal or endothelial cells, which is these-called 'adult stem cell plasticity phenomenon' [3,15-19]. These studies have documented the existence of donor genetic material in those tissues of recipients after allo-HSCT [6,8,9]. Up to now, no objective source for patients with allo-HSCT can demonstrate her real personal identification. It will be more difficult to check the forensic identification after allo-HSCT, as the innate hematopoietic and lymphoid cells of the patient could be replaced by cells derived from the donors.

POI is a rare disorder. In patients with primary amenorrhea, the incidence of POI ranges from 2% to 10%. Patients with POI have an increased risk of hypothyroidism, adrenal insufficiency, bone loss, cardiovascular disease, infertility, emotional distress, and premature death [20]. The goals of treatment for induction of puberty in patients with delayed puberty caused by allo-HSCT are to promote the development of secondary sexual characteristics, including induction of menses, induction of a pubertal growth spurt and normal height, acquisition of peak bone mass and promotion of uterine growth and maturation. Accomplishing these goals requires a fine balance of

estrogen and progesterone that mimics the natural secretion pattern of sex hormones. In adolescent girls and young women, hormone therapy with estrogen and progestin is replacing what the ovary should have naturally produced at that age. Adolescents with POI who desire childbearing in the future also have the options of oocyte donation and adoption.

CONCLUSIONS

As patients with primary amenorrhea and chromosomal abnormalities who had been treated with sex-mismatched allo-HSCT would be misdiagnosed as DSD, collecting medical history and undergoing related gene analysis are important to confirm the personal identification in clinical practice.

REFERENCES

1. Fritz MA, Speroff L. Clinical gynecologic endocrinology and infertility. 8th edition. Philadelphia: Wolters Kluwer Health/Lippincott Williams & Wilkins; 2011. <https://goo.gl/NVGieJ>
2. Marsh CA, Grimstad FW. Primary amenorrhea: diagnosis and management. *Obstet Gynecol Surv.* 2014; 69: 603-612. <https://goo.gl/TmnY4b>
3. Hong YC, Liu HM, Chen PS, Chen YJ, Lyou JY, Hu HY, et al. Hair follicle: a reliable source of recipient origin after allogeneic hematopoietic stem cell transplantation. *Bone Marrow Transplant.* 2007; 40: 871-874. <https://goo.gl/54qenE>
4. Bond JW. Value of DNA evidence in detecting crime. *J Forensic Sci* 2007; 52: 128-136. <https://goo.gl/aD9U49>
5. McCann SR, Crampe M, Molloy K, Lawler M. Hemopoietic chimerism following stem cell transplantation. *Transfus Apher Sci.* 2005; 32: 55-61. <https://goo.gl/d31SX3>
6. Durnam D, Anders K, Fisher L, O'Quigley J, Bryant E, Thomas E. Analysis of the origin of marrow cells in bone marrow transplant recipients using a Y-chromosome-specific in situ hybridization assay. *Blood.* 1989; 74: 2220-2226. <https://goo.gl/yPjT62>
7. Wessman M, Ruutu T, Volin L, Knuutila S. In situ hybridization using a Y-specific probe-a sensitive method for distinguishing residual male recipient cells from female donor cells in bone marrow transplantation. *Bone Marrow Transplant.* 1989; 4: 283-286. <https://goo.gl/RUD2Fs>
8. Bader P, Holle W, Klingebiel T, Handgretinger R, Niethammer D, Beck J. Quantitative assessment of mixed hematopoietic chimerism by polymerase chain reaction after allogeneic BMT. *Anticancer Res.* 1996; 16: 1759-1763. <https://goo.gl/erGKhP>
9. Zhou Y, Li S, Zhou J, Wang L, Song X, Lu X, et al. DNA profiling in blood, buccal swabs and hair follicles of patients after allogeneic peripheral blood stem cells transplantation. *Leg med (Tokyo).* 2011; 13: 47-51. <https://goo.gl/zKkwKK>
10. Jacewicz R, Lewandowski K, Rupa Matysek J, Jedrzejczyk M, Brzezinski PM, Dobosz T, et al. Donor-derived DNA in hair follicles of recipients after allogeneic hematopoietic stem cell transplantation. *Bone marrow transplantation* 2010; 45: 1638-1644. <https://goo.gl/WxJsJ4>
11. Stern M, Passweg JR, Locasciulli A, Socie G, Schrezenmeier H, Bekassy AN, et al. Influence of donor/recipient sex matching on outcome of allogeneic hematopoietic stem cell transplantation for aplastic anemia. *Transplantation.* 2006; 82: 218-226. <https://goo.gl/3qEjYa>
12. Meirow D, Nugent D. The effects of radiotherapy and chemotherapy on female reproduction. *Hum Reprod Update.* 2001; 7: 535-543. <https://goo.gl/2eBUi2>
13. Apperley J F, Reddy N. Mechanism and management of treatment-related gonadal failure in recipients of high dose chemoradiotherapy. *Blood Reviews.* 1995; 9: 93-116. <https://goo.gl/bQMiwg>
14. Huang H, Tian Q. Primary amenorrhea after bone marrow transplantation and adjuvant chemotherapy misdiagnosed as disorder of sex development. A case report. *Medicine (Baltimore).* 2016; 95: 5190. <https://goo.gl/jDu6K3>
15. Mezey E, Chandross KJ, Harta G, Maki RA, Mckercher SR. Turning Blood into Brain: Cells Bearing Neuronal Antigens Generated in Vivo from Bone Marrow. *Science.* 2000; 290: 1779-1782. <https://goo.gl/sY18ea>
16. Theise ND, Badve S, Saxena R, Henegariu O, Sell S, Crawford JM, et al. Derivation of hepatocytes from bone marrow cells in mice after radiation-induced myeloablation. *Hepatology.* 2000; 31: 235-240. <https://goo.gl/HxfhPp>
17. Orlic D, Kajstura J, Chimenti S, Jakoniuk I, Anderson SM, Li B, et al. Bone marrow cells regenerate infarcted myocardium. *Nature.* 2001; 410: 701-705. <https://goo.gl/LauZxK>
18. Krause DS, Theise ND, Collector MI, Henegariu O, Hwang S, Gardner R, et al. Multi-organ, multi-lineage engraftment by a single bone marrow-derived stem cell. *Cell.* 2001; 105: 369-377. <https://goo.gl/sqFfo3>
19. Jiang Y, Jahagirdar BN, Reinhardt RL, Schwartz RE, Keene CD, Ortizgonzalez XR, et al. Pluripotency of mesenchymal stem cells derived from adult marrow. *Nature.* 2002; 418: 41-9. <https://goo.gl/oHn5Hw>
20. Tao XY, Zuo AZ, Wang JQ, Tao FB. Effect of primary ovarian insufficiency and early natural menopause on mortality: a meta-analysis. *Climacteric.* 2016; 19: 27-36. <https://goo.gl/iWnvwV>