



American Journal of Clinical & Medical Images

Case Report

Paraneoplastic Pseudoachalasia Secondary to Ovarian Carcinoma: a Hard Pill to Swallow - @

Mrinali Shetty* and Yuvraj Chowdhury

Internal Medicine Resident, Saint Peter's University Hospital, New Brunswick NJ, USA

***Address for Correspondence:** Mrinali Shetty, Internal Medicine Resident, Saint Peter's University Hospital, 254 Easton Ave, New Brunswick, NJ 08901, USA, Tel: +191-762-871-91; Fax: +732-745-0406; ORCID: orcid.org/0000-0003-3263-5134; E-mail: mshetty@saintpetersuh.com

Submitted: 17 December 2017; Approved: 14 February 2018; Published: 15 February 2018

Cite this article: Shetty M, Chowdhury Y. Paraneoplastic Pseudoachalasia Secondary to Ovarian Carcinoma: a Hard Pill to Swallow. American J Clin Medical Imag. 2018;1(1): 001-004.

Copyright: © 2018 Shetty M, et al. This is an open access article distributed under the Creative Commons Attribution License, which permits unrestricted use, distribution, and reproduction in any medium, provided the original work is properly cited.

INTRODUCTION

Achalasia cardia is an uncommon disorder with an incidence of 1.6 per 100,000 people [1]. Pseudoachalasia is even more infrequent. Its prevalence is estimated at 2.4 to 4% amongst patients diagnosed with achalasia. Pseudoachalasia refers to the dilatation of the oesophagus mimicking achalasia - due to narrowing of the distal oesophagus but from reasons other than primary denervation. The most common cause of pseudoachalasia is malignant involvement of the lower esophageal sphincter of which 53.9% are primary malignancies and 14.9% are secondary [2]. Another mechanism of pseudoachalasia in the setting of malignancy is paraneoplastic involvement however this is a rarity. Paraneoplastic pseudoachalasia has been reported from tumours arising from small cell and adenocarcinoma of the lung, carcinoma of the gastric cardia, pleural mesothelioma and bronchial carcinoid [2-4] however never from the ovary. Here we report the first such case.

CASE REPORT

A 78 year old Caucasian female with known Stage IIIc Ovarian Cancer diagnosed 1½ years ago, presented with the complaint of persistent vomiting that began 8 months ago but which had acutely worsened over the week preceding presentation. The frequency of episodes had increased from 3-4 a day to 10-12 a day. She could neither keep solid food nor liquids down. She had bothersome dry heaving throughout the day associated with an unsatisfactory sensation of eructation's which she could not bring up. She also noticed having unintentionally lost 15 lbs. over the last 2 months. However, she did not have any abdominal pain or change in her bowel habits. On evaluation, she was hemodynamically stable. She appeared cachectic and pale with generalized muscle wasting. Mucous membranes were dry. Her abdomen was distended with scars of a previous TAH-BSO seen. Palpation revealed multiple palpable nodules. She was not tender to the touch and had active bowel sounds. Lower extremities exhibited pitted edema up to the ankles. Her basic metabolic panel showed no evidence of hypochloremia, hypokalemia or alkalosis as expected in chronic vomiting. The urine was concentrated but otherwise unrevealing. A plain radiograph of the chest revealed a widened mediastinum (Figure 1). At this point, we wanted to further investigate with a barium swallow, however given the patient's degree of deconditioning, she deferred. Thus instead, we ordered a CT scan of the chest without contrast.

The CT scan showed a megaesophagus with an air fluid level but without obvious stricturing at the cardio-esophageal junction (Figure 3-6). This was then compared with a CT scan done 1 year ago which showed a normal appearing collapsed esophagus (Figure 2). An Esophagogastroduodenoscopy (EGD) was performed which revealed a uniformly dilated esophagus filled with fluid. The walls were aperistaltic. The scope was able to pass through the lower esophageal junction and advanced into the stomach. A total of 3 liters of fluid was aspirated. After the scope, the patient's goals of care were revised and she entered hospice care, thus suspending any further diagnostic intervention.

Given the rapidity of onset (within 1 year as demonstrated by comparing CT scans), advanced age (achalasia usually presents before age 50) and that there was diffuse involvement of the esophagus with no visible mural involvement - primary achalasia was ruled out as this generally affects only the lower third of the esophagus. This appeared to be a more generalized motility disorder. In the setting of an active

malignancy it was therefore concluded that this is most likely due to paraneoplastic antibody formation against the myenteric plexus. This was supported by searching the literature that revealed multiple examples of paraneoplastic pseudoachalasia, as described below.

DISCUSSION

Hypothesized by Howarth in 1919 [5], the syndrome was first described by Ogilvie in 1947 [6]. The word "achalasia" translates to "failure to relax". Pseudoachalasia refers to dilatation of the esophagus mimicking achalasia but instead is due to narrowing of the distal esophagus from causes other than primary denervation. The most common cause of pseudoachalasia is direct extension of tumour cells into the Lower Esophageal Sphincter (LES).

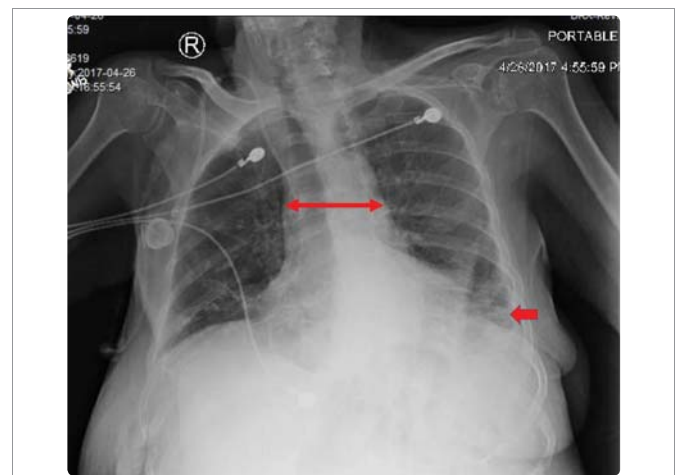


Figure 1: Chest radiograph revealing a widened mediastinum (long arrow). Also note absence of fundic gas bubble (short arrow).

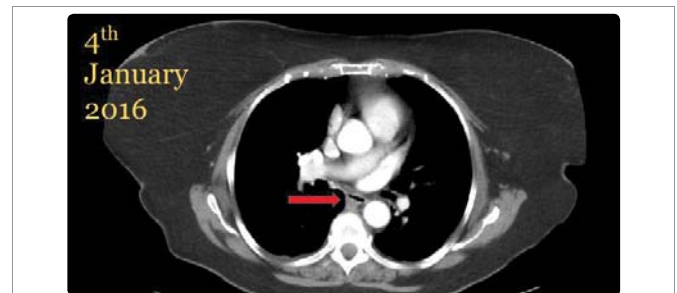

Figure 2: CT scan from 1 year ago showing normal appearing, collapsed esophagus (arrow).

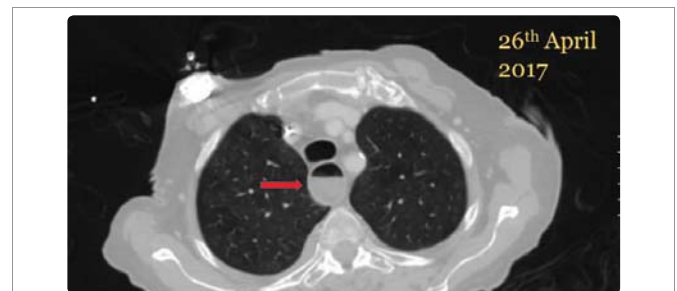

Figure 3: CT scan of the chest showing markedly dilated esophagus with a clear air fluid level (arrow).

Adenocarcinoma of the gastric fundus has been linked to 70% of such cases [7]. Less commonly pseudoachalasia may occur secondary to metastatic seeding to the LES from a distant tumour. Both these processes can lead to either disruption of the inhibitory tone on the LES or its circumferential mechanical obstruction. Other etiologies of pseudoachalasia include benign conditions (mediastinal fibrosis, amyloidosis [8] and pancreatic pseudocyst), post-surgical complications (post gastric banding or anti-reflux surgery [9-11]) and CNS disorders (meningomyelocele, Arnold-Chiari malformation and post-encephalitic) [4]. On rare occasions, as seen in our patient, malignancy can cause formation of paraneoplastic antibodies which interfere with the neuromuscular transmission at the myenteric plexus thereby leading to pseudoachalasia. In such cases, no gross anatomic pathology can be detected along the esophagus. The most common antibody associated with this kind of paraneoplastic motility disturbance is ANNA-1 (Anti-Hu) [12,13]. Kashyap et al in their paper on Enteric Autoantibodies and Gut Motility Disorders note that it is molecular mimicry and subsequent cross reactivity

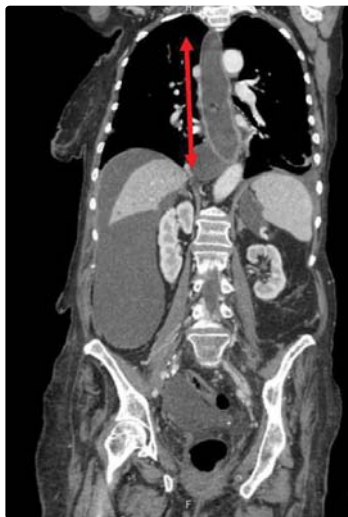


Figure 4: CT scan of the chest, abdomen and pelvis in coronal view. The mega-esophagus filled with debris is marked by the adjacent arrow.

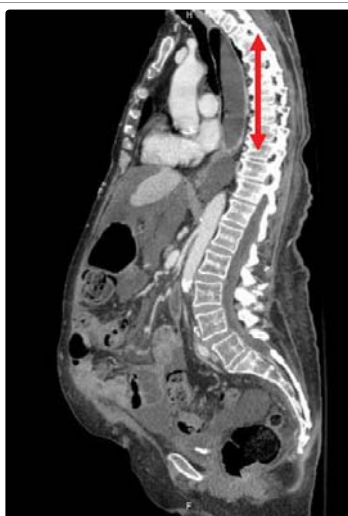

Figure 5: Sagittal view of the dilated esophagus with an air fluid level. Note: the patient is lying horizontally.

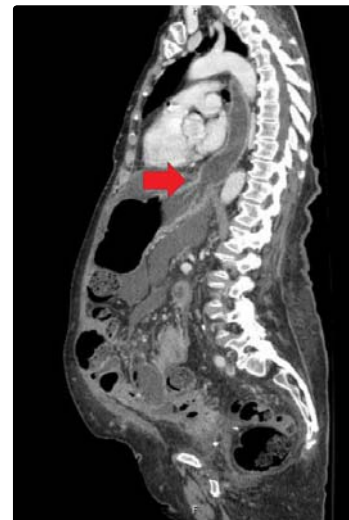

Figure 6: Another sagittal view of the esophagus. This time, the LES is better visualized and characteristic "bird's beaking" of achalasia is absent.

between onconeural antigens and neurons in the myenteric plexus that is responsible for esophageal dysfunction and achalactic transformation.

Ovarian carcinomas are known to produce ANNA-1. However ovarian carcinomas have never been linked to Pseudoachalasia. Other neoplasms that have shown to express ANNA-1 include breast, prostate, and lymphomas. Antibodies such as calcium channel antibodies have also been associated with gastric dysmotility but their association is not as well established as ANNA-1. Purkinje Cell Cytoplasmic Autoantibody type 1 (PCA1) or anti-Yo antibodies may also be expressed by ovarian and breast carcinomas. These were originally used as a marker for paraneoplastic cerebellar degeneration but have also been linked to paraneoplastic gastric dysmotility.

It is difficult to differentiate Pseudoachalasia from idiopathic achalasia by conventional techniques of radiology, manometry or endoscopy [14]. Some clues that point toward Pseudoachalasia are: (i) rapid progression of symptoms (mean duration of less than 10 months) (ii) an older population (most commonly seen in the 7th and 8th decades of life) (iii) an underlying malignancy (iv) recent anti-reflux surgical interventions involving the lower esophagus and stomach. Conversely, one must screen for malignancies in a patient with achalasia-like symptoms who presents with weight loss. A key distinguishing feature that sets apart pseudoachalasia from other primary and secondary causes of achalasia is the immediate and complete reversal of the dysmotility on addressing the underlying disease process. Given that our patient had disseminated disease with a poor prognosis, this was not an option. In advanced refractory cases some degree of palliation can be achieved with the use of stents or pneumatic dilatation to maintain transit. However, the pathology persists and outcomes with these modalities are poor. Our patient wished for no further interventions.

CONCLUSION

Rapidly progressing achalasia like symptoms (mean duration of 10 months) in an older population, with evidence of weight loss and in the setting of active malignancy such as in our patient should raise suspicion for Pseudoachalasia. Mechanisms implicated include direct or metastatic invasion by the tumour and rarely, circulating

paraneoplastic antibodies that cross react with inhibitory neurons in the myenteric plexus. Some such antibodies isolated include ANNA-1 (anti-Hu), Calcium channel antibodies and PCA1 (anti-Yo). Though ANNA-1 and PCA-1 have been shown to be produced by ovarian carcinomas, there is no literature linking ovarian carcinomas with Pseudoachalasia which makes this the first unique case of its kind. Management revolves around reversal of the primary pathology and if not, palliative interventions such as esophageal stenting or pneumatic dilatation to keep the transit passage patent.

REFERENCES

1. Sadowski DC, Ackah F, Jiang B, Svenson LW. Achalasia: incidence, prevalence and survival. A population-based study. *Neurogastroenterol Motil.* 2010; 22: 256-261. <https://goo.gl/qrVshU>
2. Lee HR, Lennon VA, Camilleri M, Prather CM. Paraneoplastic gastrointestinal motor dysfunction: clinical and laboratory characteristics. *Am J Gastroenterol.* 2001; 96: 373-379. <https://goo.gl/QpU4sH>
3. Can B, Balli F, Korkmaz U, Yilmaz H, Can FI, Celebi A. Achalasia secondary to lung adenocarcinoma. *Korean J Intern Med.* 2015; 30: 250-251. <https://goo.gl/ScRnJo>
4. Gockel I, Eckardt VF, Schmitt T, Junginger T. Pseudoachalasia: a case series and analysis of the literature. *Scand J Gastroenterol.* 2005; 40: 378-385. <https://goo.gl/4Ljm1X>
5. Howarth W. discussion on dilatation of the oesophagus without anatomical stenosis. *Proc R Soc Med.* 1919; 12: 64. <https://goo.gl/91cf6n>
6. Ogilvie H. The early diagnosis of cancer of the oesophagus and stomach. *Br Med J.* 1947; 2: 405-407. <https://goo.gl/nyii4EG>
7. Kahrlas PJ, Kishk SM, Helm JF, Dodds WJ, Harig JM, Hogan WJ. Comparison of pseudoachalasia and achalasia. *Am J Med.* 1987; 82: 439-446. <https://goo.gl/yTui5J>
8. Benjelloun M, Peng CL, Heritier F, Roger M. [Pseudoachalasia due to amyloidosis treated by botulinum toxin]. *Rev Med Interne.* 2007; 28: 188-190. <https://goo.gl/mXo2B1>
9. Chuah SK, Chung-MK, Keng-Liang W, Changchien CS, Tsung-Hui Hu, Chi-Chih Wang, et al. Pseudoachalasia in a patient after truncal vagotomy surgery successfully treated by subsequent pneumatic dilations. *World J Gastroenterol.* 2006; 12: 5087-5090. <https://goo.gl/xwxT9W>
10. Lai CN, Krishnan K, Kim MP, Dunkin BJ, Gaur P. Pseudoachalasia presenting 20 years after Nissen fundoplication: a case report. *J Cardiothorac Surg.* 2016; 11: 96. <https://goo.gl/v3axbr>
11. Lipka S, Katz S. Reversible Pseudoachalasia in a Patient with Laparoscopic Adjustable Gastric Banding. *Gastroenterol Hepatol.* 2013; 9: 469-471. <https://goo.gl/CLj8Cg>
12. Kashyap P, Farrugia G. Enteric Autoantibodies and Gut Motility Disorders. *Gastroenterol Clin North Am.* 2008; 37: 397-410. <https://goo.gl/2vYFGn>
13. Dropcho EJ. Remote neurologic manifestations of cancer. *Neurol Clin.* 2002; 20: 85-122. <https://goo.gl/LRXztk>
14. Tucker HJ, Snape WJ Jr, Cohen S. Achalasia secondary to carcinoma: manometric and clinical features. *Ann Intern Med.* 1978; 89: 315-8. <https://goo.gl/2UXwTz>