



Scientific Journal of Clinical Research in Dermatology

Case Report

Newly Diagnosed Sweet's Syndrome in an adult Patient with a Longstanding Common Variable Immunodeficiency - @

Y Turkowski^{1*}, M. Mahalingam^{1,2} and N Konnikov^{1,2}

¹Department of VA Boston Healthcare System, Jamaica Plain VA, Boston, MA

²Department of Tufts University School of Medicine, Boston, MA

***Address for Correspondence:** Y Turkowski, VA Boston Healthcare System, Jamaica Plain VA, Boston, MA, E- mail: lyyavi@yahoo.com

Submitted: 12 December 2017; **Approved:** 26 December 2017; **Published:** 28 December 2017

Cite this article: Turkowski Y, Mahalingam M, Konnikov N. Newly Diagnosed Sweet's Syndrome in an adult Patient with a Longstanding Common Variable Immunodeficiency. Sci J Clin Res Dermatol. 2017;2(2): 043-045.

Copyright: © 2017 Turkowski Y, et al. This is an open access article distributed under the Creative Commons Attribution License, which permits unrestricted use, distribution, and reproduction in any medium, provided the original work is properly cited.

ABSTRACTS

Sweet's Syndrome (SS) is an idiopathic disease characterized by various skin lesions including tender erythematous papules, plaques, or nodules on the face, neck, trunk, and upper extremities, and associated with pyrexia and malaise. Common Variable Immunodeficiency (CVID) is a disease of unknown etiology. Intrinsic B-cell defects and abnormalities in helper T cell-mediated activation of B cells lead to IgG, IgA, and occasionally IgM antibody deficiencies cause recurrent bacterial infections.

We present an adult patient with long-lasting history of CVID treated with Intravenous Immunoglobulin (IVIG) who subsequently developed SS. To the best of our knowledge only two cases of co-occurrence of these two clinical entities have been described in the literature.

We have consulted a patient with CVID who was hospitalized with tender, erythematous, well-demarcated papulo-nodular lesions on both hands and tender draining erythematous nodules on the right knee and calf. In addition, he developed a painful deep red nodule on the right buttock area. His blood culture and cutaneous cultures from draining lesions on the leg were negative. A skin biopsy revealed neutrophilic dermatosis consistent with SS. Therapy with minocycline resulted in a rapid and complete resolution of SS.

Although the etiopathogenesis of SS is unknown, investigators believe that interleukin (IL)-2, and interferon- γ may play a role in the development of SS.

There are two cases of pediatric-onset SS who subsequently were diagnosed with CVID. In our case an adult patient with long-standing CVID subsequently developed SS.

CASE REPORT

Sweet's Syndrome (SS) is an idiopathic disease characterized by various skin lesions including tender erythematous papules, plaques, or nodules. SS is associated with fever, malaise, peripheral blood neutrophilia, and an elevated erythrocyte sedimentation rate. [1]. Common Variable Immunodeficiency (CVID) is a primary immunodeficiency of unknown etiology requiring life-long Intravenous Immunoglobulin (IVIG) replacement therapy. Intrinsic B-cell defects and abnormalities in helper T cell-mediated activation of B cells lead to IgG, IgA, and occasionally IgM antibody deficiencies cause recurrent bacterial infections [2].

We report a rare case of an adult patient with long-lasting history of CVID treated with IVIG who subsequently developed SS. To date only two pediatric cases of co-occurrence of SS and CVID have been described in the literature [3,4].

A 70-year-old white man with a history of CVID on prolonged IVIG replacement therapy presented with tender, erythematous, well-demarcated papulonodules on the dorsal hands and tender draining erythematous nodules on the right knee and the right calf. In addition, he developed a painful deep red nodule on the right buttock. He denied having fever, chills, prior trauma, or any new medications.

The patient's past medical history revealed similar tender, sometimes draining lesions on the body presented intermittently for the last few years which typically subsided with courses of antibiotics and with warm compress applications. His PMH was remarkable for vitiligo, affecting his face and distal fingers, diabetes, and atrial flutter.

The physical examination revealed multiple, well-demarcated deep red colored papulonodules on the dorsal hands (Figure 1) and two draining lesions on the medial side of the right knee (Figure 2), and on the posterior aspect of the right calf. In addition, he had draining cystic mass on the left medial buttock located superior to the rectum. Differential diagnoses included bacterial infection, leukemia cutis, leukocytoclastic vasculitis, and SS. The punch biopsy was performed. Given his history of CVID and Methicillin-Resistant Staphylococcus Aureus (MRSA) infection, the patient was started on combined intravenous vancomycin and piperacillin/tazobactam therapy. However, the blood culture and cultures from draining

lesions on the leg were negative. His laboratory studies showed mild anemia and neutrophilia. A diagnostic work up for occult malignancy was negative.

Histopathological examination of the lesion from the right dorsal hand demonstrated a dense interstitial, predominantly neutrophilic infiltrate with abundant apoptotic debris, extravasated erythrocytes, and reactive vasculitis (Figure 3), findings compatible with Sweet's syndrome, in the absence of an infectious etiology.

The combined intravenous vancomycin and piperacillin/tazobactam therapy resulted in *no* significant difference in symptoms of SS and therapy with doxycycline was initiated. However, due to developed photosensitivity reaction, patient was switched to minocycline 100 mg twice a day. Therapy with minocycline resulted in a rapid and complete resolution of SS.

SS, known as acute febrile neutrophilic dermatosis, was first described by Dr. Sweet in 1964. Investigators believe that Interleukin (IL)-2, and interferon- γ may play a role in the development of SS [5].

According to Esterly, tetracyclines have been effective in reducing neutrophil chemotaxis [6]. Clinical improvement has been reported

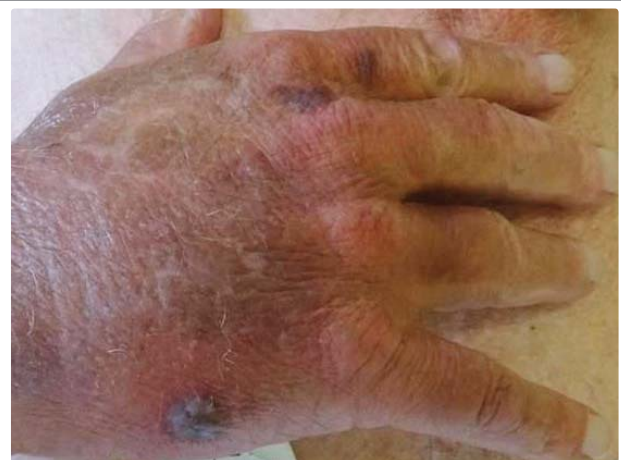

Figure 1: Well-defined deep red papulonodules on the dorsal surface of the right hand.

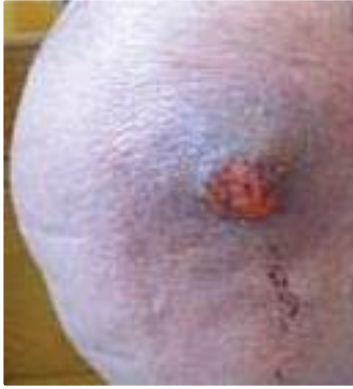

Figure 2: A firm erythematous draining nodule on the right knee.

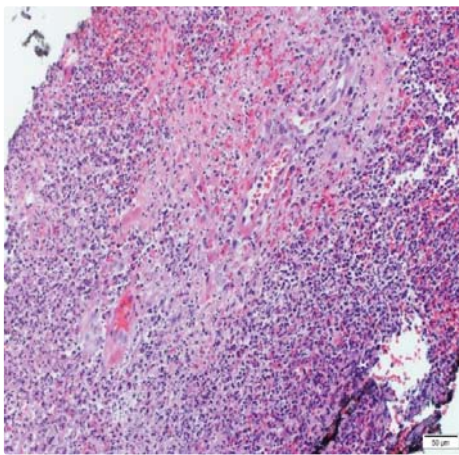


Figure 3: Medium power view of the biopsy specimen from the right dorsal hand shows a dense interstitial, predominantly neutrophilic infiltrate with abundant apoptotic debris, extravasated erythrocytes, and reactive vasculitis (hematoxylin-eosin).

in the studies using minocycline in neutrophilic dermatoses [7]. Minocycline attenuates the pro-inflammatory process in keratinocytes by reducing the protease-activated receptor 2-mediated production of IL-8 [8]. Both doxycycline and minocycline are highly lipophilic, however minocycline is 5-fold more lipophilic than doxycycline, and has 47% higher concentration in skin than in serum [9].

Given the patient's history of recurrent erythematous nodules over the body and the absence of histological examination, we raised the possibility of recurrent SS in the past.

To date, this is the first case of the adult patient with long-standing CVID associated with SS. We emphasize the necessity of tissue biopsy for the definitive diagnosis and proper management of SS.

REFERENCES

1. Cohen P R. Sweet's syndrome – a comprehensive review of an acute febrile neutrophilic dermatosis. *Orphanet Journal of Rare Diseases*. 2007; 2: 34. <https://goo.gl/zxHCJY>
2. Coraglia A, Galassi N, Fernandez Romero D.S. Common Variable Immunodeficiency and Circulating TFH. *Journal of Immunology Research*, 2016; 2016: 4951587. <https://goo.gl/gAKMph>
3. O'Regan G M, Ho W L, Limaye S, Keogan MT, Murphy GM, Sweet's syndrome in association with common variable immunodeficiency. *Clinical and Experimental Dermatology*. 2009; 34: 192-194. <https://goo.gl/YL3sfM>
4. Cook Q. Idiopathic, Refractory Sweet's Syndrome Associated with Common Variable Immunodeficiency. *Journal of Allergy and Clinical Immunology*. 2017; 139: 109 <https://goo.gl/9mp6Uz>
5. Giasuddin AS, El-Orfi AH, Ziu MM, El-Barnawi NY. Sweet's syndrome: Is the pathogenesis mediated by helper T cell type 1 cytokines? *Journal of the American Academy of Dermatology*. 1998; 39: 940-943. <https://goo.gl/Kr4VJK>
6. Esterly NB, Koransky JS, Furey NL, Trevisan M. Neutrophil chemotaxis in patients with acne receiving oral tetracycline therapy. *Arch Dermatol*. 1984; 120: 1308-1313. <https://goo.gl/ozZKyD>
7. Sapadin AN, Fleischmajer R. Tetracyclines: nonantibiotic properties and their clinical implications. *J Am Acad Dermatol*. 2006; 54: 258-265. <https://goo.gl/k6Av2A>
8. Ishikawa C, Tsuda T, Konishi H, Nakagawa N, Yamanishi K. Tetracyclines modulate protease-activated receptor 2-mediated proinflammatory reactions in epidermal keratinocytes. *Antimicrob Agents Chemother*. 2009; 53: 1760-1765. <https://goo.gl/jZ1t8s>
9. Macdonald H, Kelly RG, Allen ES. Pharmacokinetic studies on minocycline in man. *Clin Pharmacol Ther*. 1973; 14: 852-861. <https://goo.gl/RJfA4r>