



International Journal of Hepatology & Gastroenterology

Case Report

Left Hepatic Lobe Herniating through Sternotomy Incision - Ⓜ

Amer HA. Ani^{1*}, Mustafa YRA. Badra², Sabah A. Kaisy¹, Hesham Abdulmoneim¹, Hassan Abdulhakim¹, Zahir A. jowher², Elteгани E. Ahmed¹ and Gada A. Khalid¹

¹Department of General Surgery, Sheikh Khalifa medical city, Sheikh Khalifa General Hospital, Ajman, United Arab Emirates

²Department of diagnostic radiology, Sheikh Khalifa medical city, Sheikh Khalifa General Hospital, Ajman, United Arab Emirates

***Address for Correspondence:** Amer Hashim Al Ani, Department of General Surgery, Sheikh Khalifa medical city, Sheikh Khalifa General Hospital, Ajman, United Arab Emirates, Tel: +00-971-562-623-722; E-mail: ameralqadi2002@yahoo.com

Submitted: 04 October 2017 **Approved:** 12 October 2017 **Published:** 15 October 2017

Cite this article: Ani AHA, Badra MYRA, Kaisy SA, Abdulmoneim H, Abdulhakim H, et al. Left Hepatic Lobe Herniating through Sternotomy Incision. Int J Hepatol Gastroenterol. 2017;3(3): 056-059.

Copyright: © 2017 Ani AHA, et al. This is an open access article distributed under the Creative Commons Attribution License, which permits unrestricted use, distribution, and reproduction in any medium, provided the original work is properly cited.

ABSTRACT

Introduction: Liver herniation through surgical incision is very rare. Moreover, it is exceptional for the left hepatic lobe to herniate through sternotomy incision.

Presentation of the case: We present herein a 66 year old woman admitted to ER complains about upper abdominal pain. Abdominal CT scan showed herniation of part of left hepatic lobe through previous sternotomy incision. Conservative measures were successful in managing her symptoms.

Discussion: Till now only few cases of liver herniation through scar of sternotomy have been documented.

Conclusion: Although it is rare, left hepatic lobe may herniate through sternotomy incision.

Keywords: Left lobe liver; Sternotomy; Incisional hernia

INTRODUCTION

It is very rare for a liver or part of it to be involved in a hernia. Congenital and traumatic diaphragmatic hernias are the most common hernias to contain liver [1,2]. Only few cases of liver herniated through incision of sternotomy were documented in medical literatures [3]. Asymptomatic cases were treated conservatively [3]. While, those with symptoms were treated by surgery to repair the hernia and reduce its content (liver) [4].

CASE REPORT

We report a 66 year old women presented to ER with upper abdominal pain following heavy meal. The pain was burning in nature, radiates to the back. Associated with nausea. There was no vomiting, fever, chills or itching. She noticed no changes in her bowel habit, color or consistency. She identified a non-painful swelling protruded from her upper abdomen 2 years ago. She is asthmatic, diabetic, had history of myocardial infarction. Three years back she had Coronary Artery Bypass Grafting (CABG). She is on aspirin, amlodipine, frusemide, Insulin and nebulizer. She is not smoker. Not drinking alcohol.

On examination

She was pale, not jaundiced. Her vital signs were with in normal. By inspection; there was a scar of previous sternotomy extending from the chest to upper part of abdomen. A 6X 6 centimeter mass was protruding from the scar. The mass was soft by palpation. It was not tender. The rest of the abdomen was soft, apart from mild tenderness in epigastric region. Bowel sounds were active.

Laboratory tests revealed

Low Hemoglobin (9.80 gm/dl), low serum iron (5.90 umol/l), high blood sugar (7.8 mmol/l), high blood Urea (10.70 mmol/l), low Albumin (30.0 gm/l), low serum Calcium (2.09 mmol/l), normal T4 Free (15.82 pmol/l), low T3 Free (3.52 pmol/l), high TSH (4.64 mIU/l), high D-Dimer (1.30 mg/l), high Hemoglobin A1c (8.1 %), high C reactive protein (19.9 mg/l), normal liver function test, normal lipase and amylase. Serum electrolytes were with in normal. All the abnormal parameters were corrected. ECG, echocardiography was done for the patient. Then her cardiac problems were managed by the cardiologist. OGD (esophagogastroduodenoscopy) showed reflux gastritis. This was controlled by proton pump inhibitors.

Computed tomography abdomen revealed herniation of the left lobe of the liver (figure 1, 2) with surrounded fat through a large epigastric defect just below a previous sternotomy incision (figure 1, 2). The herniated part appear iso-dense to the normal liver. Severe

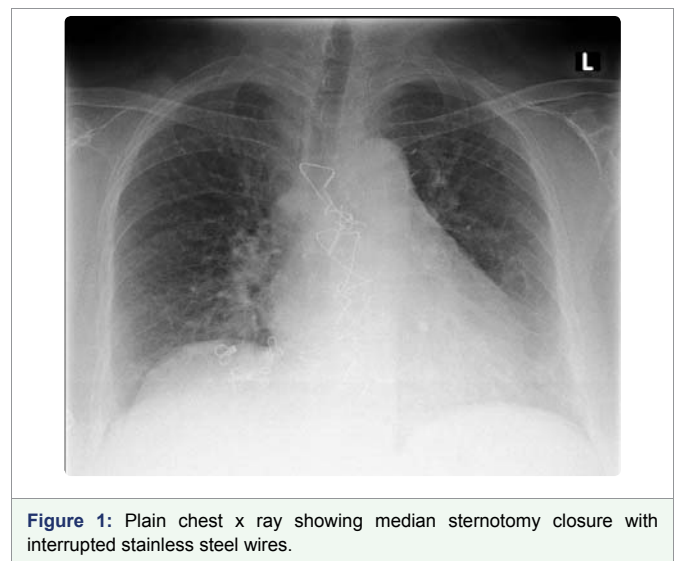


Figure 1: Plain chest x ray showing median sternotomy closure with interrupted stainless steel wires.

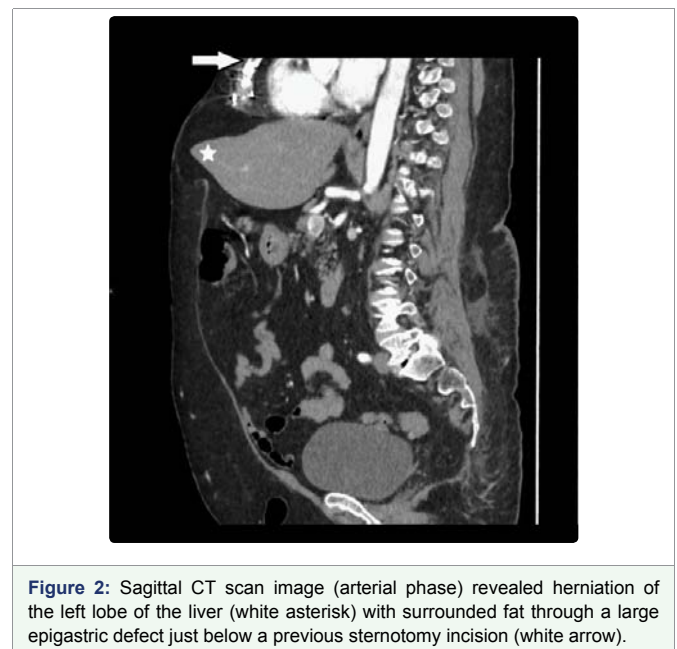


Figure 2: Sagittal CT scan image (arterial phase) revealed herniation of the left lobe of the liver (white asterisk) with surrounded fat through a large epigastric defect just below a previous sternotomy incision (white arrow).

intervertebral disc generation seen with possibility of multiple disc prolapse.

After two days of conservative management in hospital, her pain was relieved, her blood sugar was controlled, and her parameters

were good. She was discharged home in a good general condition. For the next three months patient was asymptomatic.

DISCUSSION

Liver hernia is very rare [1,5] (Table 1). Congenital diaphragmatic defects, and blunt trauma diaphragmatic rupture are the most common documented causes resulting in this hernia [2]. Obesity and previous abdominal surgery are other less common causes [6].

Up to May 2015 only three cases have been reported for liver herniation through scar of previous of CABG surgery as in this case [5].

Abdominal pain, discomfort, nausea, vomiting, jaundice, dyspnea, confusion and swelling are the most common presenting symptoms [1-3]. In our case the presenting symptom was abdominal

pain.

Left lobe of the liver is the most common part of the liver to herniate through abdominal wall [5]. This hernia may progress to an incarcerated incisional hernia [7,8]. Median sternotomy for coronary artery bypass [3,9] (this is the surgery in this case), midline laparotomy for trauma, intestinal obstruction [7], orthotopic liver transplantation [10], open cholecystectomy [6] and for choledochotomy to remove liver hydatid cyst [11]. Right subcostal incision for open cholecystectomy and right flank incision via a retroperitoneal approach for nephrectomy [8], are the comments operations complicated by liver hernia. Briffaut and colleagues [12] report an entity described in neonatal period known as exclusive hepatocele, in which the liver is part of omphalocele contents.

Transabdominal ultrasound, CT scan and magnetic resonance imaging can usually appropriately determine liver as the hernia content [1-35,9,13]. CT scan confirmed left lobe of liver as a content of incisional hernia in our case. Conservative therapy should be considered first in these rare patients, especially asymptomatic patients and those whose symptoms were minimal [3,9]. In this case we were able to control the symptoms with symptomatic treatment. However, surgical therapy may be an option for patients with more severe complaints [7].

CONCLUSION

Left lobe of liver rarely herniate through abdominal extension of sternotomy incision following CABG (Coronary artery bypass grafting). A CT scan can confirm the diagnosis. Conservative treatment is usually successful.

FUNDING

This study did not receive funding from any external source.

INFORMED CONSENT

Written consent was obtained from the patient for the publication of this case report.

REFERENCES

- Mullassery D, Baath ME, Jesudason EC, Losty PD. Value of liver herniation in prediction of outcome in fetal congenital diaphragmatic hernia: a systematic review and meta-analysis. *Ultrasound Obstet Gynecol.* 2010; 35: 609-614. <https://goo.gl/4nF97q>
- Kim HH, Shin YR, Kim KJ, Hwang SS, Ha HK, Byun JY, et al. Blunt traumatic rupture of the diaphragm: sonographic diagnosis. *J Ultrasound Med.* 1997; 16: 593-598. <https://goo.gl/54ivbH>
- Shanbhogue A, Fasih N. Hepatobiliary and pancreatic: Herniation of the liver. *J Gastroenterol Hepatol.* 2009; 24: 170. <https://goo.gl/M9PACb>
- Neelamraju Lakshmi H, Saini D, Om P, Bagree R. A ventral incisional hernia with herniation of the left hepatic lobe and review of the literature. *BMJ Case Reports.* 2015. <https://goo.gl/AUmNy1>
- Sharique A, Tanveer PS, Nisha Mandhane, Sandesh D, Sangram K. A rare case of herniation of liver through incision of cabg: A case report and review of literature. *Int J Res Med Sci.* 2015; 3: 1817-1819. <https://goo.gl/GQaYiQ>
- Nuno-Guzman CM, Arroniz-Jauregui J, Espejo I, Valle- Gonzalez J, Butus H, Molina-Romo A, et al. Left hepatic lobe herniation through an incisional anterior abdominal wall hernia and right adrenal myelolipoma: a case report and review of the literature. *J Med Case Reports.* 2012; 6: 4. <https://goo.gl/DGfHgX>
- Eken H, Isik A, Buyukakincak S, Yilmaz I, Firat D, Cimen O. Incarceration of the left hepatic lobe in incisional hernia: a case report. *Ann Med Surg (Lond).* 2005; 11: 169-171. <https://goo.gl/Q8imzv>

Year (reference)	Age (sex)	Complaint	Surgery	Duration (year)	Herniating lobe of liver	Therapy
2000 (3)	56 (f)	Right upper quadrant pain of 6 months duration	No	-	Left lobe (through the rectus muscle)	conservative
2009 (4)	48 (m)	Discomfort and swelling in the epigastrium during 2 weeks	Coroner artery bypass surgery	2	Left lobe	conservative
2012 (5)	81 (m)	Acute right upper quadrant abdominal pain	Coroner artery bypass surgery	7	Left lobe	conservative
2004 (6)	45 (f)	Upper abdominal pain of 3 months duration	Liver transplantation	2	Left lobe	conservative
2005 (7)	73 (f)	Right upper quadrant pain of 6 months duration	(1)Cholecystectomy (2)Ileus*	6 4	Left lobe	Conservative
2012 (8)	70(f)	Right upper quadrant pain of 1 week duration	Cholecystectomy	20	Left lobe	Surgery
2014 (9)	75 (f)	Right upper quadrant pain of 4 months duration	(1) CC (2)Cystectomy	5 5	Left lobe	Conservative
2015 (present case)		Epigastric pain of 1 year duration	Coronary artery bypass surgery	3	Left lobe	Conservative

Table 1: Cases of liver incisional herniation from 2000 to 2015 [5].

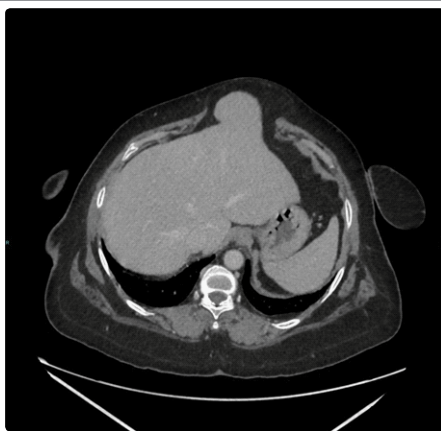

Figure 3: Axial CT scan image (venous phase) shows the herniated liver parenchyma through the epigastric anterior abdominal wall defect, the herniated part appear isodense to the normal liver.

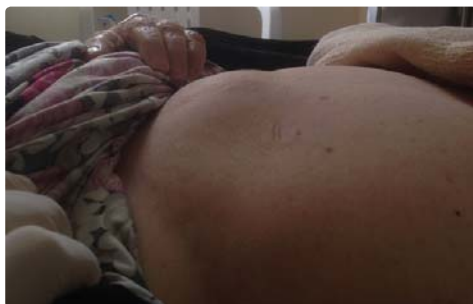

Figure 4: Incisional hernia through sternotomy incision.

8. Salemis NS, Nisotakis K, Gourgiotis A, Tsohataridis E. Segmental liver incarceration through a recurrent incisional lumbar hernia. *Hepatobiliary Pancreat Dis Int.* 2007; 6: 442-444. <https://goo.gl/pfD1SN>
9. Warbrick-Smith J, Chana P, Hewes J. Herniation of the liver via an incisional abdominal wall defect. *BMJ Case Rep.* 2012; 27: 1-3. <https://goo.gl/m6YcDS>
10. Sheer TA, Runyon BA. Recurrent massive steatosis with liver herniation following transplantation. *Liver Transpl.* 2004; 10: 1324-1325. <https://goo.gl/xz1Byw>
11. Tekin F, Arslan A, Gunsar f. Herniation of the Liver: An Extremely Rare Entity. *J Coll Physicians Surg Pak.* 2014; 24: S186-7. <https://goo.gl/iHdHSc>
12. Sabbah Briffaut E, Houfflin-Debauge V, Sfeir R, Devisme L, Dubos J-P, Puech F, et al. Liver hernia. Prognosis and report of 11 cases. *J Gynecol Obstet Biol Reprod (Paris).* 2008; 37: 379-84. <https://goo.gl/ANGuXa>
13. Matteo Bonatti, Fabio Lombardo, Norberto Vezzali, Giulia A Zamboni, Giampietro Bonatti. Blunt diaphragmatic lesions: Imaging findings and pitfalls. *World J Radiol.* 2016; 28; 8: 819-828. <https://goo.gl/bLuD5z>