



# International Journal of Reproductive Medicine & Gynecology

## Case Report

## Sexual Life of Women with Mayer-Rokitansky-Kuster-Hauser syndrome after Laparoscopic Vecchietti Vaginoplasty-Case Series -

**Aditi Rai\*, Ramesh Bettaiah, Rubina Pandit and Minal Kumbhalwar**

*Department of Obstetrics and Gynecology, Altius hospital, Bengaluru, Karnataka, India*

**\*Address for Correspondence:** Aditi Rai, Department of Obstetrics and Gynecology, Fellow in Minimal invasive gynecology surgery, Altius hospital , 6/63, 59th cross, 4th block, rajajinagar, Bengaluru, India, Tel: +995-385-2841; E-mail: aditirai004@gmail.com

**Submitted: 28 July 2020; Approved: 18 August 2020; Published: 19 August 2020**

**Cite this article:** Rai A, Bettaiah R, Pandit R, Kumbhalwar M. Sexual Life of Women with Mayer-Rokitansky-Kuster-Hauser syndrome after Laparoscopic Vecchietti Vaginoplasty-Case Series. Int J Reprod Med Gynecol. 2020;6(1): 020-024.

**Copyright:** © 2020 Rai A, et al. This is an open access article distributed under the Creative Commons Attribution License, which permits unrestricted use, distribution, and reproduction in any medium, provided the original work is properly cited.

## ABSTRACT

MRKH syndrome is characterized by uterine and vaginal aplasia. Typically, presentation is primary amenorrhea with normal secondary sexual characters, blind vagina, absence of uterus and cervix on ultrasonography with normal 46 XX karyotype. Mayer-Rokitansky-Kuser-Hauser syndrome (Rokitansky syndrome) is the frequent indication for neovaginoplasty. In this case series we describe three patient who came to us with different clinical presentation. Patients were seen at the Hospital with primary amenorrhea and fully developed secondary sexual characters. A clinical follow-up protocol, including the use of high-resolution image studies was used for diagnosis. Diagnostic procedures and current medical approaches to the treatment of MRKH are discussed, including psychological advisory, surgical procedures. Laparoscopic Vecchietti operation by the use of acrylic olive is a safe procedure to create a neovagina, which guarantees good quality of sexual life with high satisfaction for patient. Advantage of the Laparoscopy Vecchietti procedure are fast achievement of a functional vagina, absence of large scars, better patient tolerance.

**Keywords:** Laparoscopy; Mayer-Rokitansky-Kuser-Hauser syndrome; Mullerian agenesis; Primary amenorrhea; Blind vagina; Acrylic olive

## INTRODUCTION

Vaginal agenesis is the most significant congenital anomalies of female reproductive tract. Neovaginal reconstruction is one of the treatment modalities used for various congenital and acquired causes of partial or total absence of vaginal canal. The most common indication for neovaginoplasty is Mayer-Rokitansky-Kuser-Hauser syndrome (MRKH).

MRKH syndrome is characterized by uterine and vaginal aplasia. The most common presentation is primary amenorrhea with normal secondary sexual characters, blind vagina, absence of uterus and cervix on ultrasonography with normal karyotype (46XX) [1]. MRKH syndrome is mostly associated with renal, skeletal, and other anomalies. The exact incidence of Rokitansky syndrome is unknown, although a recent study estimated Vaginal agenesis (Mayer-Rokitansky-Kuser-Hauser MRKH syndrome) affects 1 in 4000 to 1 in 10000 women. Vecchietti procedure is a unique surgical technique which was first described in 1992, and then later modified via laparoscopic approach [2].

## CASE REPORT 1

A 37-year-old female, married for eight years, presented with chief complaint of dyspareunia, Primary amenorrhea and infertility. There was no history of cyclical lower abdominal pain or urinary symptoms. On examination, secondary sexual characters were well developed with normal axillary and pubic hair distribution and no palpable abdominal or inguinal mass. Vaginal examination showed normal vulva and urethral meatus, but a short (1.5 cm) blind pouch of vagina.

MRI Pelvis done which revealed rudimentary uterus and bilateral ovaries normal. Karyotyping was normal (46XX). The patient was counseled regarding on the nature of anomaly and the treatment options available to restore her sexual life and as well as the prospects of child bearing.

### Case Report 2

A 27 year old female, planning to get married in near future, presented with complaint of primary amenorrhea. She was treated with oral contraceptive pills for few months, but failed to induce her periods. Examination showed normal secondary sex characters and well-developed breasts (Tanner stage 4) with normal axillary and pubic hair distribution, no palpable abdominal masses. Local examination showed normal vulva and urethral meatus, blind pouch of vagina. On Per rectal examination uterus was not palpable (Figure 1).

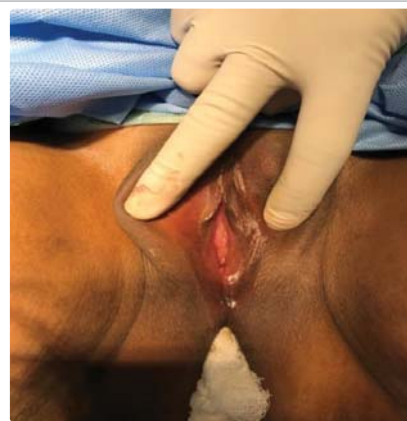

Figure 1: Blind pouch of vagina.

Abdominal ultrasound showed hypoplastic uterus with bilateral normal ovaries. Hormonal assay revealed no abnormality. Patient was counseled for vaginoplasty and she consented for the same.

## CASE REPORT 3

A 35-year-old women, with marital life of ten years, was referred to our unit with complaint of severe dyspareunia. There was no history of cyclical lower abdominal pain or urinary symptoms. She had no significant medical or family history.

Clinical examination and imaging revealed findings suggestive of MRKH syndrome. Patient was taken up for surgery after proper consent to improve her sexual life.

## PROCEDURE

All patients were explained in detail regarding the surgical procedure and the likely outcome post operation. At our center, the surgical technique predominantly followed is laparoscopic Vecchietti's vaginoplasty, as described below.

A device producing upward traction was inserted in the suprapubic area. Acrylic olive was placed in retrohymenal pouch (Figure 2), which acted as a wedge through the rectovesical space, thus creating an adequate space between the two viscera that can be maintained by dilators and sexual activity (Figure 3).

Bladder was emptied by catheterization; and adequate pneumoperitoneum was created using CO<sub>2</sub> gas. Laparoscope was introduced through the supra umbilical region (Figure 4). The

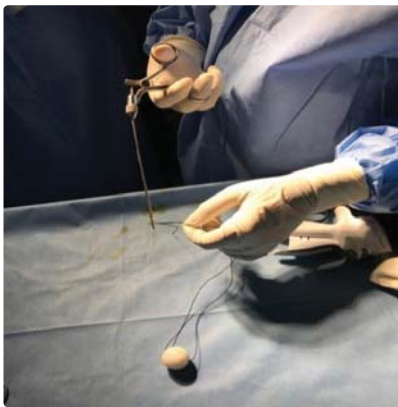traction device along with thread was temporarily placed on the supra pubic region to serve as a marking on the skin.

Adjacent to the marking, one ancillary trocar was introduced to allow accurate exploration of the abdominal and pelvic organs. Adjacent to the trocar at the level of deep inguinal ring, stab incision was made through, which Maryland forceps was introduced enter the loose sub-peritoneal connective tissue downward and medially until it reaches the fold between the bladder and the uterine rudiment (Figure 3).

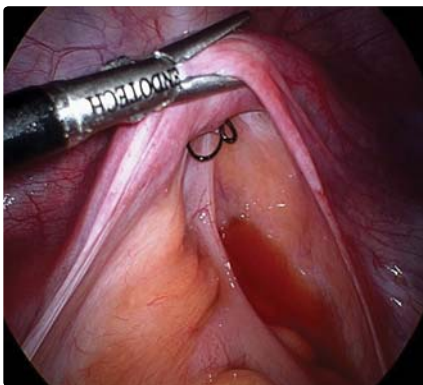
The black silk no. 4 was fed into the acrylic olive on either side and placed in retrohymenal pouch. The end of the thread is was hooked on to the port closure needle with finger guiding the needle through the blind vagina. Needle was is retrieved through the uterine rudiment intra-abdominally under laparoscopic guidance. The edge of the silk thread was is brought out on to the skin by Maryland forceps through sub-peritoneal tunnel and fixed to the traction device (Figure 5,6) which is was placed suprapubically and its tension is was graduated (Figure 7).

## POSTOPERATIVE CARE

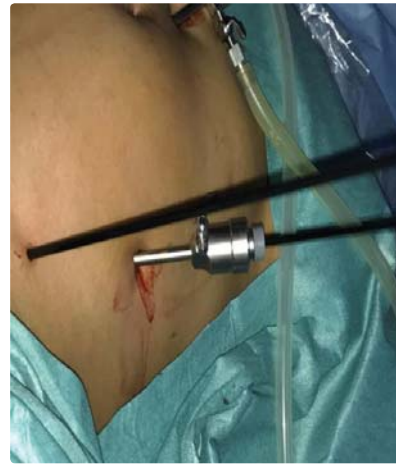All patients were admitted for a week postoperatively and gradual traction was given every day. Urethral catheter was kept inset for seven days and IV intravenous antibiotics were administered for 24 hours. Patient was started on soft diet from second day post-surgery. Traction was removed on postoperative day-7 and vaginal length was checked. All women were instructed to use dilators (soft and blunt)



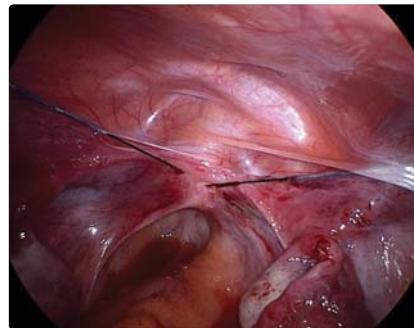
**Figure 2:** Silk thread fed into olive head needle.



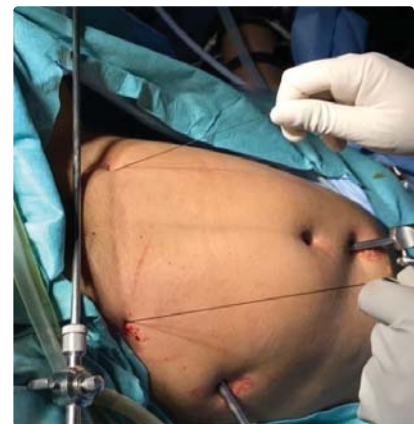**Figure 3:** Rudimentary horn held with Maryland.



**Figure 4:** Stab incision adjacent to the lateral port.



**Figure 5:** Silk thread taken out via subperitoneal tissue into the skin outside to get fixed into a traction device.



**Figure 6:** Silk thread taken out via subperitoneal tissue into the skin outside to get fixed into a traction device.

for approximately 8-10 hours per day during the first month. The dilators were made of soft latex, measuring 10cm in length, and were available in three diameters: 1.5cm, 2cm and 2.5cm. After use, patients were instructed to properly wash and sterilize them with antiseptic solution or normal water. Intercourse was allowed twenty days after removal of acrylic olive. All patients were called for follow up visit on day 15 and day 30 post surgery to check the vaginal length. Patients were comfortable and adequate vaginal length of approximately five cm was achieved in all (Figure 8,9).

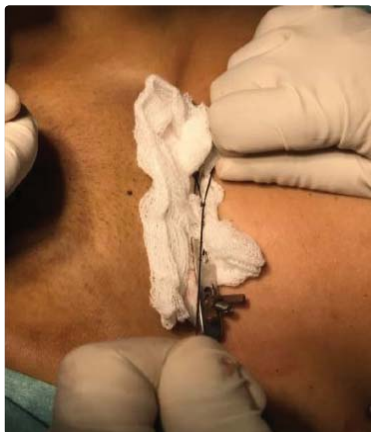

Figure 7: Silk thread fixing into traction device.

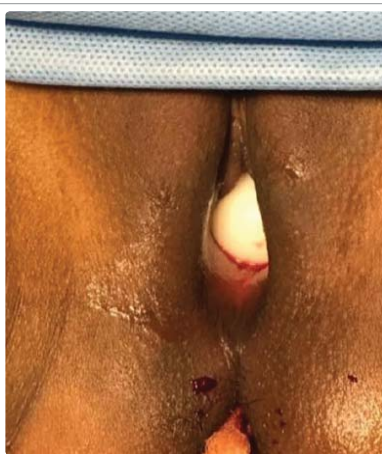

Figure 8: Acrylic olive ball onto the blind vagina.

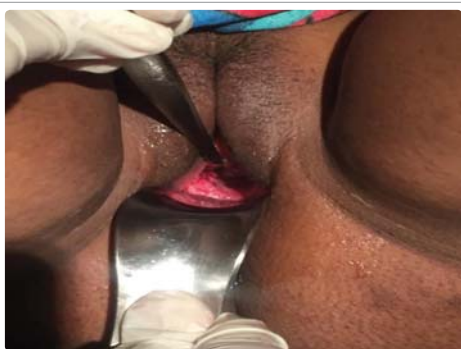

Figure 9: Vaginal length increase by 5 cm end of the week.

## DISCUSSION

### Mayer-Rokitansky-Kuster-Hauser (MRKH) syndrome

MRKH syndrome is a rare congenital disorder characterized by uterine and vaginal aplasia. Typically, patients present with primary amenorrhea with normal secondary sexual characters, blind vagina, absence of uterus and cervix on ultrasonography with normal 46 XX karyotype. Associated abnormalities of the kidneys and other organ systems are often seen.

### Other organ abnormalities

Renal abnormality (renal agenesis, ectopic kidney, horseshoe kidney and ectopic ureter) is the most common abnormality which is reported in up to 40% of women. 12-20% of women also present with skeletal abnormalities like Klippel-Fiel anomaly, fused vertebrae, radial aplasia, absent thumb, scoliosis and radial hypoplasia [3-6]. Other abnormalities reported in MRKH are auditory malformations (stapedial ankylosis, sensorineural deafness) and cardiac abnormalities (fallot tetralogy, patent ductus arteriosus, truncus arteriosus).

A neovagina can be formed either by intermittent vaginal dilatations (non-surgical methods) or by vaginoplasty (surgical method). In certain cases of primary vaginal atresia non-surgical method may be useful. Vaginal reconstruction may be required in majority of the patients.

Most common procedure for vaginoplasty was used by McIndoe and Bannister [7], in which space was created between bladder and rectum and a mold which is covered by a split-thickness skin graft was used. Hojsgaard, et al. [8] study reported complications such as graft reaction, bleeding, urethrovaginal fistula, perforation of the rectum, rectovaginal fistula, and vaginal stricture after McIndoe procedure.

In an elegant study done by Fedele, et al. [9], 110 patients underwent laparoscopy vecchietti's procedure, 98% of the patients reported normal vaginal sexual activity and 97% patients attained normal vaginal length. Advantages for this procedure includes less operative time, small scar on abdomen and no complicated surgical techniques.

Another study done by Brun JL, et al. [10] also revealed good anatomical success (94.3%) and attainment of adequate vaginal length  $\geq 6$  cm post Vecchietti's procedure in patients with MRKH syndrome.

Compared to Davydov's procedure, Vecchietti's laparoscopic technique is simpler with less operative time and reduce risk of surgery related complications. Most of the data reports comparable outcomes with respect to sexual activity.

Davydov's procedure is indicated for patients with abnormalities of the external genitalia, such as female hypospadias, which is a contraindication to the creation of a neovagina by vaginal pressure, such as in the laparoscopic Vecchietti technique and Frank method.

In case of failure to achieve anatomical correction post Davydov's technique, the success rate of repeat surgery is extremely low due to difficulty in performing recanalisation of urethra vesicorectal space. On the other hand, in case of failure after Vecchietti's procedure, another technique can be attempted without major difficulties.

The modified laparoscopic Vecchietti technique is more cost-effective and less painful compare to other surgical procedure like McIndoe technique, Colon vaginoplasty, William vulvovaginoplasty. The modified laparoscopic Vecchietti technique is concluded to be a highly effective surgery technique for creating neovagina in women with MRKH syndrome, in view of low morbidity and cost effectiveness, high success rate and less surgery related complication.

## RESULT

All patient were followed up after procedure at regular intervals. None of them faced any difficulty during sexual intercourse.



## CONCLUSION

MRKH syndrome is characterized by uterine and vaginal aplasia. Typically, presentation is primary amenorrhea with normal secondary sexual characters, blind vagina, absence of uterus and cervix on ultrasonography with normal 46 XX karyotype. Patient and family need urgent psychological counseling. Vecchietti vaginoplasty is one of the most popular method and minimally invasive procedure with good outcomes. Advantage of this procedure includes fast achievement of a functional vagina, absence of large scars, better patient tolerance and maintenance of privacy. Pregnancy can be achieved later by *in vitro* fertilization techniques and surrogacy.

## REFERENCES

1. Evans TN, Poland ML, Boving RL. Vaginal malformations. Am J Obstet Gynecol. 1981; 141: 910-920. DOI: 10.1016/s0002-9378(16)32683-7.
2. Fedele L, Bianchi S, Frontino G, Ciappina N, Fontana E, Borruto F. Laparoscopic findings and pelvic anatomy in Mayer-Rokitansky-Kuster-Hauser syndrome. Obstet Gynecol. 2007; 109: 1111-1115. DOI: 10.1097/01.AOG.0000260872.28368.46.
3. Oppelt P, Renner SP, Kellermann A, Brucker S, Hauser GA, Ludwig KS, et al. Clinical aspects of Mayer-Rokitansky-Kuester-Hauser syndrome: Recommendations for clinical diagnosis and staging. Hum Reprod. 2006; 21: 792-797. DOI 10.1093/humrep/dei381
4. Morcel K, Camborieux L, Guerrier D. Programme de Recherches sur les Aplasies Mulleriennes, Mayer-Rokitansky-Kuster-Hauser (MRKH) syndrome. Orphanet J Rare Dis. 2007 Mar 14; 2:13. DOI: 10.1186/1750-1172-2-13.
4. Varner RE, Younger JB, Blackwell RE. Mullerian dysgenesis. J Reprod Med. 1985; 30: 443-450.
5. Strubbe EH, Willemsen WN, Lemmens JA, Thijn CJ, Rolland R. Mayer-Rokitansky-Kuster-Hauser syndrome: Distinction between two forms based on excretory urographic, sonographic, and laparoscopic findings. Am J Roentgenol. 1993; 160: 331-334. DOI: 10.2214/ajr.160.2.8424345
6. McIndoe AH, Bannister JB. An operation for the cure of congenital absence of the vagina. J Obstet Gynaecol Br Emp. 1938; 45: 490-494.
7. Hojsgaard A, Villadsen I. McIndoe procedure for congenital vaginal agenesis: Complications and results. Br J Plast Surg. 1995; 48: 97-102. DOI: 10.1016/0007-1226(95)90104-3.
8. Fedele L, Bianchi S, Tozzi L, Borruto F, Vignali M. A new laparoscopic procedure for creation of a neovagina in Mayer-Rokitansky-Küster-Hauser syndrome. Fertil Steril. 199; 66: 854-857.
9. Brun JL, Belleannée G, Grafeille N, Aslan AF, Brun GH. Long-term results after neovagina creation in Mayer-Rokitansky-Kuster-Hauser syndrome by Vecchietti's operation. Eur J Obstet Gynecol Reprod Biol. 2002; 103: 168-172. DOI: 10.1016/S0301-2115(02)00031-3.